

Extent of Injury Workshop Part II Advanced Topics



Disclaimer

Every case has its own facts, and this workshop is being offered for educational purposes. Any content of this presentation is not authoritative. A DD must base their determination of the extent of injury on the certifying examination, the medical record and EBM pertinent to the case they are analyzing.



Extent of Injury Question

Was the accident or incident giving rise to the compensable injury a ***substantial factor*** in bringing about the additional claimed injuries or conditions, and...

without it, the additional injuries or conditions would not have occurred?

Include an explanation of the basis for your opinion, NOT just your opinion.



EOI Analysis: Understanding the Question

- Important medical/legal question in workers' compensation
- *You* give your opinion and rationale as to which injuries are caused by accident and which are not
- Support your opinion, from a medical perspective, within the legal framework
- You provide medical expertise to inform those reading your report, including an Administrative Law Judge
- We will review legal standards for you to consider



Legally Sufficient Analysis

Let's go through some examples of Appeals Panel Decisions (APDs) with examples of doctors in different roles and how they approached an analysis.

- These are some examples of causation opinions that:
 - That were missing elements of the causation analysis and did not meet the standard.
 - Met the required standard.
- This is the context to be thinking about as we work through the steps for causation analysis.



EXTENT of INJURY

Sufficient Causation Analysis:

APD 130235

- The Appeals Panel (AP) reversed the Administrative Law Judge (ALJ) who stated that there was not adequate expert evidence to show a hand infection was a result of the puncture wound.
- The Appeals Panel stated **all 3 opinions were good**. In particular, the RME and Peer Review addressed the time lapse between the incident (puncture wound), and the subsequent infection, debridement and loss of function.
- ***This APD was in a time frame where diagnoses were listed on the DWC -32 and considered to be the starting point for the EOI discussion.***



EXTENT of INJURY

Sufficient Causation Analysis: **APD**

130235: DD ANALYSIS

Original Compensable Diagnosis:

Puncture wound of the left hand (palm)

EXTENT of INJURY

Sufficient Causation Analysis: APD

130235: DD ANALYSIS

Additional Claimed Diagnosis / Conditions:

- Palmar Space Infection.
- Tissue debridement and scar formation following surgical treatment of infection.
- Severe loss of left wrist and hand function secondary to infection and treatment of infection.



EXTENT of INJURY

Sufficient Causation Analysis: **APD**

130235: DD ANALYSIS

“The injury to the left hand and wrist was due to infection and subsequent surgical procedures to treat the infection caused by a penetrating wound from a nail gun. The mechanism of the puncture wound to the palmar hand injury, mechanism of injury, and outcome are consistent with the physical exam.”



EXTENT of INJURY

Sufficient Causation Analysis: APD

130235: RME ANALYSIS

“This claimant had a puncture wound to the left wrist in late April 2006. Several months later he went to the emergency room with an extremely infected left wrist. With the degree of infection found at the time of his visit to the emergency room, that infection had clearly been going on for quite some time.”



EXTENT of INJURY

Sufficient Causation Analysis: **APD**

130235: RME ANALYSIS

“While there is a significant length of time, approximately three months between the date of injury here and the infection being treated at the hospital, with no other reason for this claimant to have had a deep abscess such as he had, it is reasonable to believe that the compensable injury was the proximate cause of the deep palmar staph infection that this claimant was treated for in July 2006.”



EXTENT of INJURY

Sufficient Causation Analysis: APD

130235: PEER REVIEW

“The claimant sustained a puncture wound to the left wrist area. This ultimately resulted in a deep-seated infection secondary to abscess formation.

It is not unusual that this type of infection can take some time to develop in all medical probability however, the puncture wound was the cause of this infection. It should be understood that [the claimant] was compromised secondary to diabetes. This made him more susceptible to developing the infection.”

EXTENT of INJURY

Sufficient Causation Analysis: **APD 130235:**

HOW WOULD YOU HAVE EXPLAINED?

- Make sure that what is clear to you as a medical doctor is clear to the reader of your report
- Expand on the location of the wound and where the deep palmar space is located and extends to, as a way to understand your conclusion
- This anatomy and definition will allow the reader to visualize the pathology better.
- The MAGIC WORDS of MEDICAL PROBABILITY means nothing if there is no explanation to back it up.



EXTENT of INJURY

Let's look at an Insufficient Causation Analysis: **APD 111881:**

Original Compensable Diagnosis:

- Lumbar sprain / Lumbar strain

Extent of Injury Issue:

- Lumbar disc bulges at L1-2, L5-S1,
- L4-5 osteophyte.

This APD was in a time frame where diagnoses were listed on the DWC -32 and considered to be the starting point for the EOI discussion.



EXTENT of INJURY

Let's look at an Insufficient Causation Analysis: **APD 111881:**

- The ALJ adopted the treating doctor's causation opinion.
- In this case, the Appeals Panel reversed the ALJ as to some of the additional claimed injuries.
- They stated that the treating doctor's opinions were conclusory, and therefore insufficient.



EXTENT of INJURY

APD 111881: Treating Doctor's Conclusive Analysis

- *“Lumbar disc herniations and symptoms arise **solely** and directly from his work-related incident. It is impossible to comment on the potential shear forces without having observed the incident itself.”*
- The causation letter pointed out that the claimant was working full time, was asymptomatic at the time of the accident, and the injury was significant enough to warrant a trip to the emergency room where the MRI documented lumbar “disc herniations.”



EXTENT of INJURY

APD 111881: Treating Doctor's Conclusory Analysis

- As per the APD, *“The treating doctor does not specifically mention the MRI finding of an osteophyte at the L4 level or explain how the mechanism of injury could have caused the lumbar disc bulges at the specified levels at issue”*.
- Also note that, the treating doctor called the bulges that were the additional claimed injuries, herniations.



EXTENT of INJURY

APD 111881: Designated Doctor's Analysis

- DD diagnosed the claimant with *“lumbar and thoracic strains/sprains aggravating degenerative disc disease and degenerative joint disease”*.
- As per the APD, Dr. S *“does not specifically mention the extent-of-injury conditions at issue or attempt to explain how the mechanism of injury could have caused the claimed conditions at issue”*.



EXTENT of INJURY

APD 111881: Designated Doctor's Analysis

- The DD used the term degenerative disc disease (DDD) instead of the terms lumbar disc bulges at L1-2, L5-S1, and L4-5 osteophyte, as noted on the DWC 32, without explanation.
- With an explanation that DDD and degenerative joint disease (DJD) were synonymous to the Box C diagnoses / conditions (if they were) AND an explanation as to why they were aggravated, this could potentially have been adopted.



Questions Regarding EOI Appeals Panel Analysis?





Extent of Injury – Part II



**EXTENT OF INJURY
ANALYSIS**



REPORT WRITING



Extent of Injury Part II

Analysis & Report Writing

- Report writing for Designated Doctor evaluations is not something that is taught in our advanced education.
- DON'T assume that the readers of our report have any medical knowledge.
- Imagine presenting medical evidence to laypeople
- Your report should be:
 - Thorough and “Connect the Dots”
 - Should flow from beginning to end in logical format
 - Be legally sufficient



EOI Report Writing - Case 1

TREATING DOCTOR EVALUATION: 02/28/2023

- John Smith is a 55-year-old male
- Date of injury of 02/14/2023.

MECHANISM / HISTORY OF INJURY:

- After he stepped out of his 18-wheeler, the Injured Employee's (IE) foot slipped on some gravel, and he fell onto his anterolateral left knee. Denied his knee twisted or hyperextended prior to the fall. He was partially able to brace his fall with his left arm and denied significant injury to his left arm.



EOI Report Writing - Case 1

TREATING DOCTOR EVALUATION: 02/28/2023

COMPLAINTS:

- At the time of the injury, he had mainly anterior to anterolateral knee pain
- Still in that location, but “the whole knee hurts”.
- Some swelling developed over the first week.
- No complaints of instability or mechanical symptoms
- Reported he “*never had right or left knee pain before*”.
- Some initial left forearm pain and bruising resolved



EOI Report Writing – Case 1

TREATING DOCTOR EVALUATION: 02/28/2023

CLINICAL EXAM:

- The left knee had a well healed surgical scar consistent with prior scope portals.
- The left knee aligned was in varus in neutral stance
- Palpable hypertrophic changes of the joint line present medially > laterally
- No warmth and minor soft tissue swelling vs effusion of the left knee.
- Tender anterolateral knee, including patellofemoral region.
No medial joint line pain nor left forearm pain.

EOI Report Writing – Case 1

TREATING DOCTOR EVALUATION: 02/28/2023

TD CLINICAL EXAM / ASSESSMENT

- Bilateral knee ranges of motion were reported as ~ 0 to 120. Mostly limited by leg girths.
- Provocative testing difficult due to BMI, but no obvious laxity with AP drawer or Varus / Valgus stress

X-rays: Tricompartmental OA of the left knee without acute findings or significant effusion

Assessment:

1. Left Knee Strain
2. Left Knee Contusion

Plan:

1. RICE, 2. RTW with restrictions on climbing, 3. PT



EOI Report Writing – Case 1

TD - Reevaluations during and after 8 visits of PT

- **Complaints and symptoms**

About the same. More global knee pain

- **Clinical exam:**

ROMS and stability ~ the same. Some later decline in ROM. No exam or report on the contralateral knee.

- **Assessment:**

1. Knee Strain, 2. Knee Contusion, 3. Pre-existing OA,
4. High BMI

- **Plan:**

1. MRI- Evaluate for fracture / bone contusion
2. Continue HEP



EOI Report Writing – Case 1

RADIOLOGY @ ~ 6 weeks after DOI:

04/05/2023 – Supreme Imaging - MRI Left Knee:

Indications were “*knee pain*”.

Imaging demonstrated:

1. Severe medial and moderate patellofemoral compartment osteoarthritis.
2. Lateral compartment chondromalacia without overt osteoarthritis.
3. Maceration / complex tear of the medial meniscus with extrusion of the body and involvement of the posterior root.



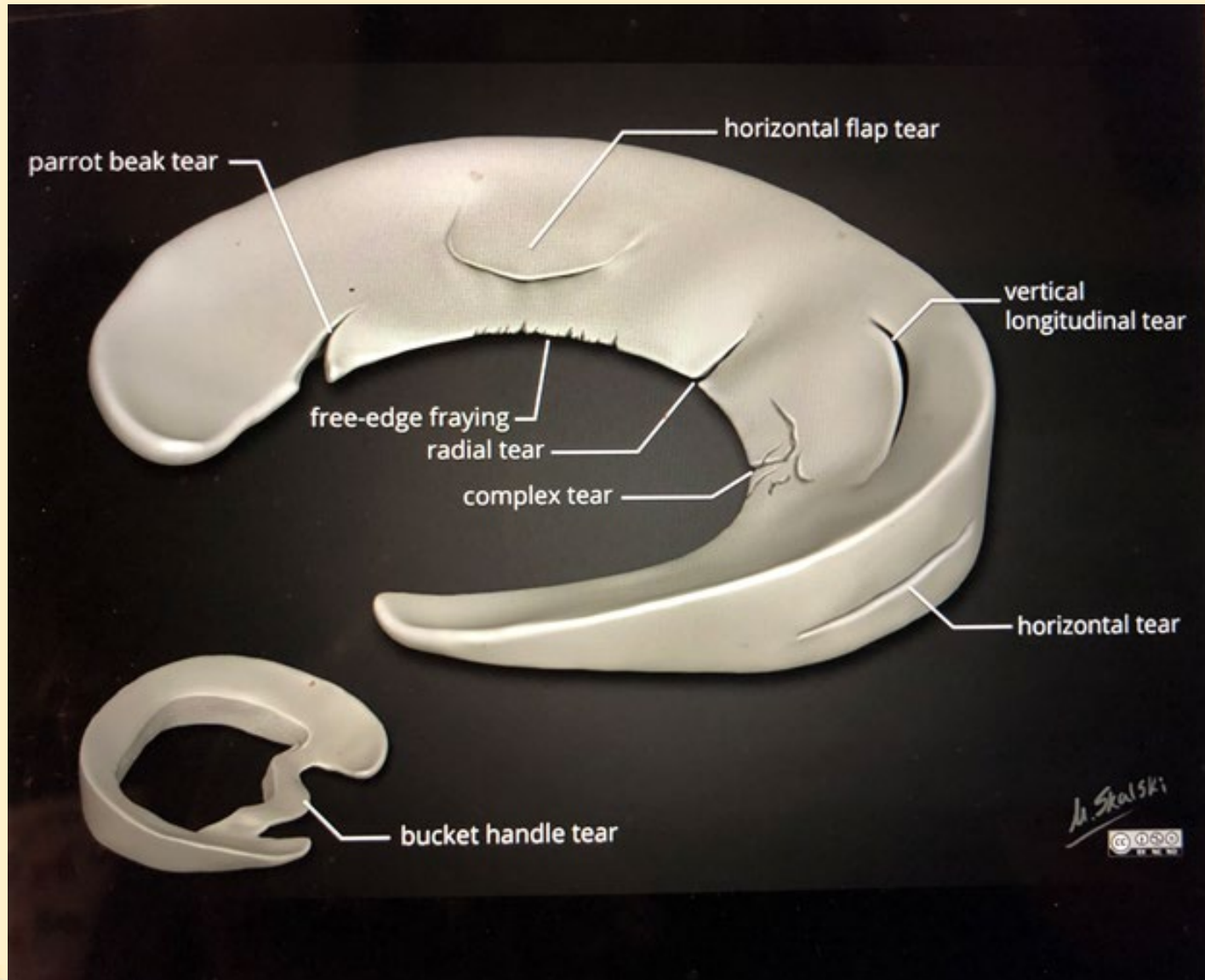
EOI Report Writing – Case 1

**04/05/2023 – Supreme Imaging - MRI Left Knee
(continued)**

4. High grade partial if not complete tear of the tibial attachment of the ACL without surrounding edema
5. The MCL and LCL are intact. There is some laxity of the MCL without intra-ligamentous, peri-ligamentous edema or at the attachments
6. Small joint effusion.
7. No bone contusion at the patellofemoral or tibiofemoral compartment



EOI Report Writing - Case1





EOI Report Writing – Case 1

04/14/2023 –Orthopedic Consultation– Dr. Cutter

MOI: Slipped coming out of 18-wheeler, “twisting” the knee

Complaints: Medial and lateral knee pain

Exam: Left knee only:

Moderate joint effusion

(+) McMurray’s medial > lateral

(+) Lachman’s and Anterior Drawer

Impression: Torn Meniscus and arthritis

Plan: Total Knee Arthroplasty



EOI Report Writing – Case 1

04/28/2023 – Peer Review – Dr. Denial

“The MOI was not consistent with causing or producing the ACL tear. The osteoarthritis and the meniscal changes are degenerative and there is no evidence on exam or imaging that there was aggravation.”

Several EBM articles were provided to support the Peer opinion.

05/04/2023 – PLN-11:

“The carrier disputes that any of the findings on the MRI were caused or aggravated by the events of 02/14/2023”.



EOI Report Writing – Case 1

DWC Form 32

V. Purpose for Examination, C. To determine extent of injury

DWC032

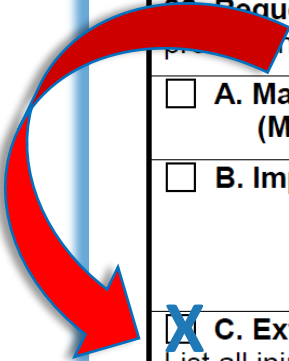
V. PURPOSE FOR EXAMINATION

Requester: Check box(es) A through G next to the issue(s) you want the designated doctor to address and provide the requested information.

- | | |
|--|---|
| <input type="checkbox"/> A. Maximum Medical Improvement (MMI) | Statutory MMI Date (if any) _____
<small>(mm/dd/yyyy)</small> |
| <input type="checkbox"/> B. Impairment Rating (IR) | MMI Date* _____ (required only if Box A is not checked)
<small>(mm/dd/yyyy)</small>

*The MMI date determined valid by a final TDI-DWC decision, court, or agreement of the parties. |

C. Extent of Injury
 List all injuries (diagnoses/body parts/conditions) in question, claimed to be caused by, or naturally resulting from the accident or incident **and** describe the accident or incident that caused the claimed injury.



EOI Report Writing – Case 1

C. Extent of Injury

List all injuries (diagnoses/body parts/conditions) in question, claimed to be caused by, or naturally resulting from the accident or incident **and** describe the accident or incident that caused the claimed injury.

Severe medial and moderate patellofemoral compartment osteoarthritis, Maceration / complex tear of the medial meniscus with extrusion of the body and involvement of the posterior root, High grade partial if not complete tear of the tibial attachment of the ACL, Lateral compartment chondromalacia without osteoarthritis, small joint effusion, MCL laxity of the MCL without edema .

IE tripped and fell on the left anterolateral knee



EOI Report Writing – Case 1 DWC Form-32

As of 6/5/2023

the DWC-032 form will no longer ask the requestor to list injuries accepted by the insurance carrier.



EOI Report Writing – Case 1

DESIGNATED DOCTOR (DD) EVALUATION MECHANISM OF INJURY (MOI):

The IE reported that he slipped coming out of 18-wheeler, twisting his left knee, jamming it on the ground, at which point his knee buckled and twisted again, which caused him to fall onto the left knee without being able to break his fall.



EOI Report Writing – Case 1

DESIGNATED DOCTOR (DD) EVALUATION

COMPLAINTS:

- The IE reported that there was immediate pain everywhere and the swelling was “massive”.
- His pain has increased over time.
- He can barely walk.
- Nothing has helped, including an injection Dr. Cutter administered on their second visit.



EOI Report Writing – Case 1

DD EVALUATION

MEDICAL HISTORY:

Conditions:

1. BMI over 45,
2. Sleep apnea,
3. Hypertension,
4. Diabetes

Surgeries:

1. Knee surgery 10 - 11 years ago, “*meniscus and scraped arthritis*”,
2. Spine surgery for spinal stenosis,
3. Right shoulder surgery 2021



EOI Report Writing – Case 1

DD EVALUATION

MEDICAL HISTORY (continued):

Prior Injuries:

1. Left knee WC injury 10 – 11 years ago, “recovered completely”
2. Football injury left knee in the late 70s,
3. Denies prior right knee injuries

Medications:

1. Oxycodone for prior back injury, since 10/02/19.
2. Verapamil for BP



EOI Report Writing – Case 1

DD EVALUATION

SOCIAL OCCUPATIONAL HISTORY:

Mr. Smith is high school educated with some college. He had been with this employer or over 15 years. They are trying to accommodate his restrictions.

REVIEW OF SYMPTOMS:

Pertinent for:

Heartburn, back pain, headaches, numbness, weakness, excess fatigue and easy bruising.

[Multiple somatic symptoms to consider.]



EOI Report Writing - Case 1

DD PHYSICAL EXAMINATION:

- Ht: 5'8" Wt: 303 lbs BP: 153/93 P: 79
- Identified by his license.
- His movement patterns in the lobby and in the exam room were consistent with demonstrated movement patterns when formally measured.
- The unaffected leg demonstrated more functional limitations than the affected leg
- Wide based gait consistent with his body habitus.



EOI Report Writing - Case 1

DD PHYSICAL EXAMINATION:

- He could perform bilateral squat to 45 degrees of knee and hip flexion, with retropatellar crepitation bilaterally, with more weight on the “affected” left leg.
- Significant difficulties with single limb balance for left AND right leg.
- The unaffected right knee **and** affected left knee demonstrated **varus** in stance, during gait and while in supine. He walked with more antalgia off the right leg.
- Single limb squat demonstrated more limitations than bilateral squat and with compensatory movements.



EOI Report Writing - Case 1

DD PHYSICAL EXAMINATION:

- The lumbar spine a longitudinal 6 – 8 cm scar, above and below the L4-L5 level.
- The iliac crests palpated to be relatively level.
- There was no obvious spasm or significant muscular guarding present in the thoracolumbar spine.
- There were symmetrically decreased side bends without end range pain (ERP). Extension was more limited than flexion with ERP. Movement patterns were consistent with age and body habitus.



EOI Report Writing - Case 1

DD PHYSICAL EXAMINATION:

- Distracted SLR in seated and supine SLR did not reproduce dural tension signs.
- FABER and FADIR test were accomplished with difficulty due to body habitus but did not cause pain referral to the affected knee.
- Attempted femoral nerve stretch tests were positive for significant bilateral hip flexor tightness, but no femoral nerve stretch signs.



EOI Report Writing - Case 1

DD PHYSICAL EXAMINATION:

- The left knee had a well healed surgical scar consistent with prior scope portals.
- The right knee was in varus and had obvious bony hypertrophic changes of the joint line mostly medial. The left knee had similar appearance.
- There is no erythema or warmth to either knee.
- Both knees had a degree of soft tissue swelling, but no significant suprapatellar effusion compared to the left.



EOI Report Writing - Case 1

DD PHYSICAL EXAMINATION:

- Knee ranges of motion were checked with handheld inclinometers as per recommended positions in the AMA Guides, 4th Edition.
 - **RIGHT:** Flexion to 115 degrees with ~ 3 degrees with lack of extension.
 - **LEFT:** Flexion to 118. There is no evidence of an extension lag. There is no evidence of a flexion contracture.
- Passive ROMS were consistent with active ROM



EOI Report Writing – Case 1

DD PHYSICAL EXAMINATION:

- **Leg circumferences:** as per AMA recommendations:

- Calves were measured at 12 cm below the patella (where circumference greatest on the right). Right 48.5 cm and left 48.5 cm.

- Thighs were measured 10 cm above the patella. Right 72 and left 71.5.



EOI Report Writing – Case 1

DD PHYSICAL EXAMINATION:

•Vascular:

- His distal limb vascular exam was normal.
- Pulses were symmetric, there was good capillary refill and normal temperature.
- There were no dystrophic skin or nail changes.
- There were no varicosities



EOI Report Writing – Case 1

DD PHYSICAL EXAMINATION:

- **Reflexes:**

- Bilateral patella were 2/4 symmetric.
- The medial hamstrings were trace present but symmetric.
- The Achilles reflexes were absent.

- **Sensory:**

- There are no obvious sensory deficits in a significant dermatomal or peripheral nerve distribution in either lower extremity.

- **Motor:**

- Manual muscle testing also revealed good intact strength in major muscle groups of proximal and distal bilateral lower extremities, with mild pain inhibition of the quads B.



EOI Report Writing - Case 1

DD PHYSICAL EXAMINATION:

KNEE PROVOCATIVE MANUEVERS:

- Based on his thigh circumferences and inflexibilities, it was difficult to perform an adequate McMurray's Test.
- LEFT KNEE (injured)**
 - Anterior drawer = ~ 3 mm with a good endpoint.
 - Posterior Drawer = negative.
 - Varus and Valgus Stress
 - 0 degrees were very stable.
 - Varus Stress at 30 degrees with mild joint line opening but with a fair to good endpoint and no complaints of pain or instability.

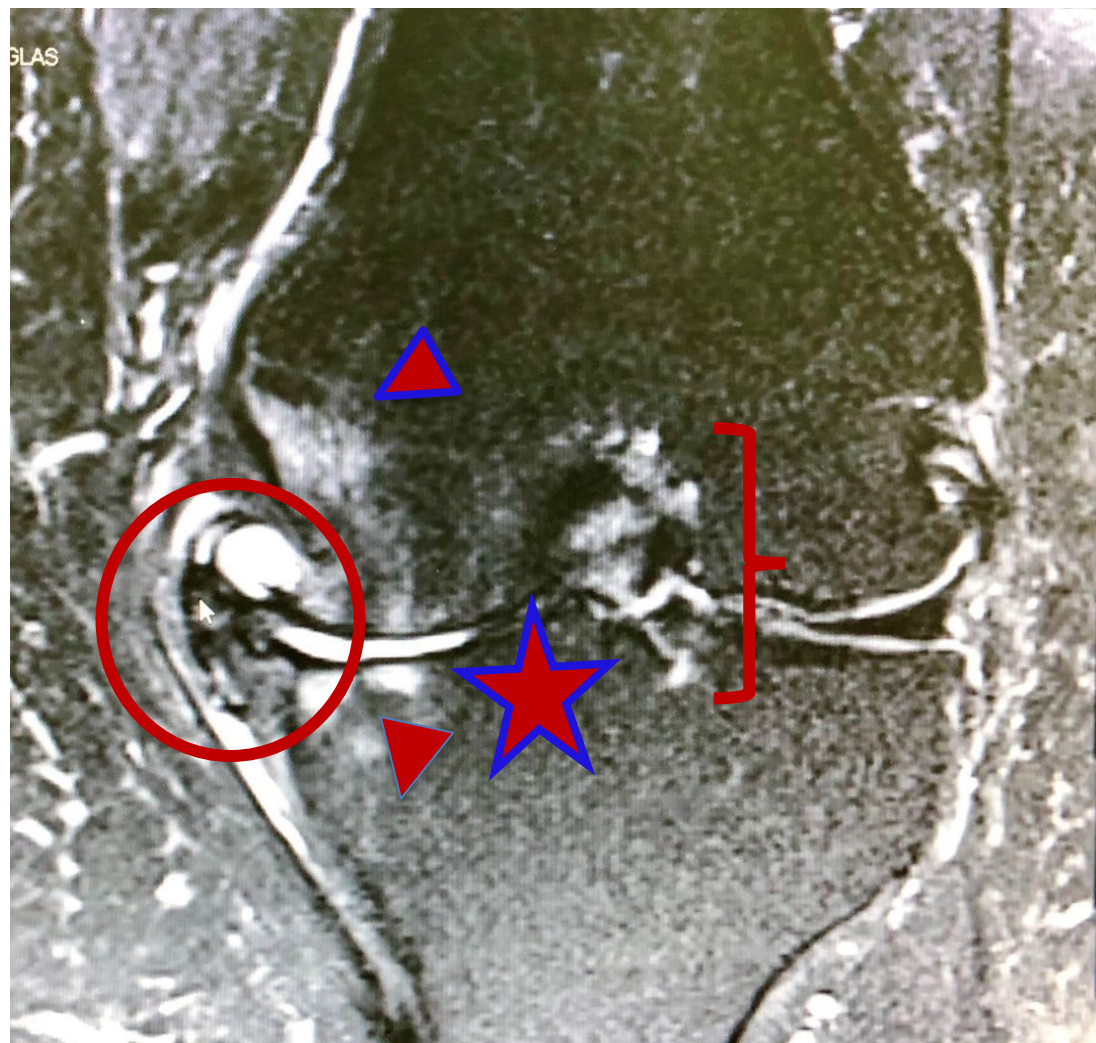
EOI Report Writing - Case 1

DD IMAGING REVIEW

MRI from 04/05/2030

CORONAL VIEW

The lateral compartment is on the right and the medial compartment is on the left. Note the remodeling of the medial tibial plateau and medial femoral condyle compared to the normal appearing lateral medial plateau and femoral condyle. The medial meniscus is extruded and there are osteophytic growths encapsulating the meniscus.



EOI Report Writing - Case 1

DD IMAGING REVIEW

MRI from 04/05/2023

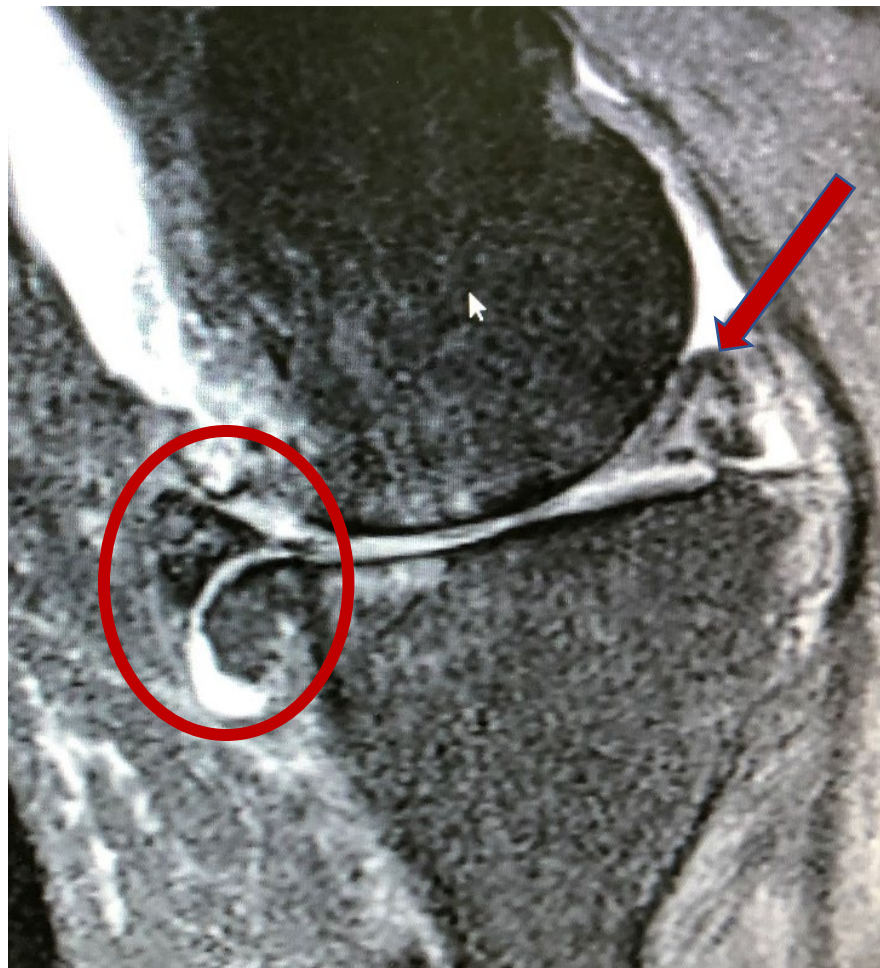SAGGITAL VIEW

at medial compartment

Anterior is on the left

Posterior is on the right.

- Circle is on the triangular anterior extruded medial meniscus with the globular osteophyte complex off the tibia
- Arrow is on the complex tear of the posterior medial meniscus
- No evidence of kissing contusions of the femur or tibia.





EOI Report Writing - Case 1

DD ORDERED X-RAYS

- **10/05/2023 – Supreme Imaging – X-rays of the lower extremity.**

- Bilateral AP views of the knee were ordered and obtained as per AMA recommendations to be completed in weightbearing with the beam 36 inches from the knee and parallel to the articular surface.
- The **purpose** of these images was to determine the alignment and the radiographic cartilage interval of the asymptomatic and symptomatic knee for the purpose of the EOI question

EOI Report Writing - Case 1

DESIGNATED DOCTOR ORDERED X-RAYS

- **10/05/2023 – Supreme Imaging – X-rays knees.**
- **Left knee** (affected knee):
 - Severe OA changes in the medial tibiofemoral and patellofemoral compartments.
- **Right knee** (unaffected):
 - Similar changes to the left.
 - There was a *“moderate degree of OA change compared to imaging completed two years prior on 10/09/18”*. \

[This individual had prior imaging of the RIGHT knee, reflecting that there were prior symptoms in the non-injured knee.]
- **Standing Alignment:**
 - Left knee with 8 degrees of varus.
 - Right knee with 12 degrees of varus

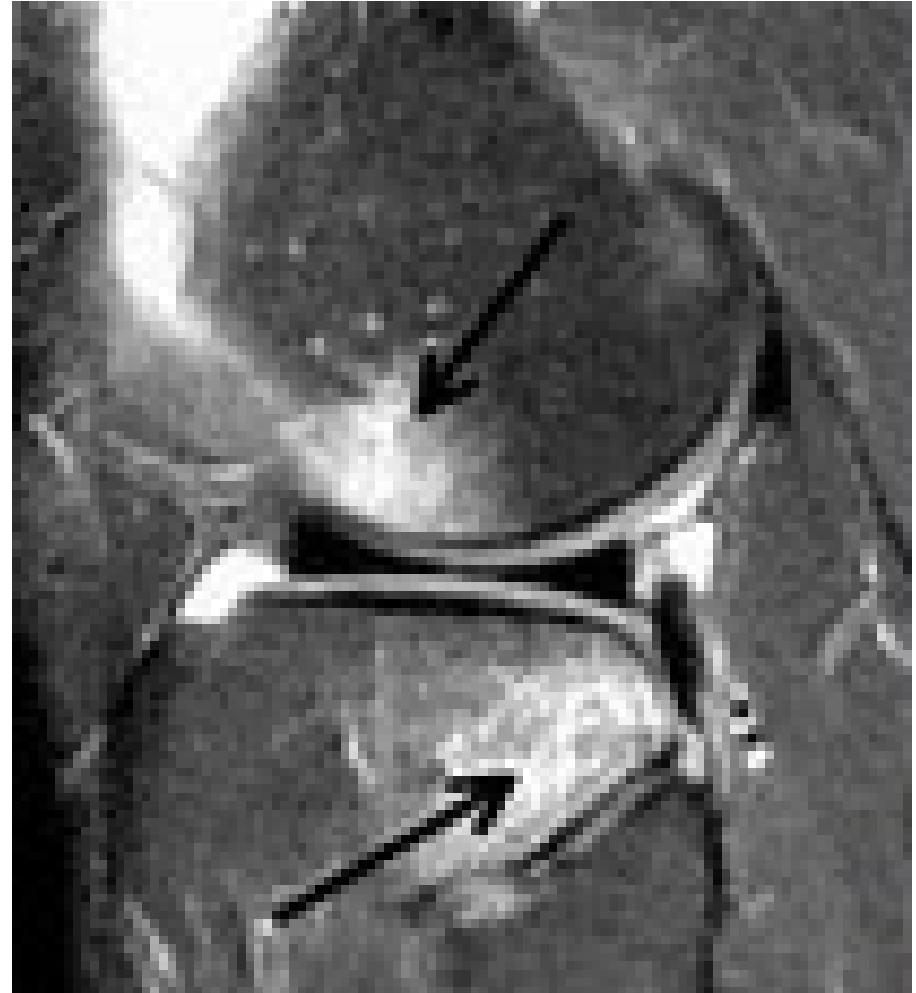
EOI Report Writing – Case 1

NOT IN THIS CASE

EBM EXAMPLE: “Kissing lesions”
from Pivot shift mechanism
in ACUTE ACL TEARS.

Note the bone contusions
on sagittal MRI in the
anterior femur and the
posterior tibia as the tibia
translates out from under
the femur.

Radiopaedia – Anterior
Cruciate Ligament Tear



EOI Report Writing - Case 1

DESIGNATED DOCTOR REPORT

- EVIDENCE BASED MEDICINE:
- What other EBM would be important to support your conclusions?
- What EBM would a doctor with an opposing opinion cite.
- Make sure that what you use for you EBM supports your opinion. Abstracts can be misleading.

EOI Report Writing - Case 1

DESIGNATED DOCTOR REPORT

DESCRIBE EACH INJURY FROM BOX 31C

+ MECHANISM OF INJURY

+ CLINICAL FINDINGS AND TIMELINE

+ EVIDENCE BASED MEDICINE

+ ANSWER QUESTIONS WITH APPROPRIATE LEGAL TERMS

SUFFICIENT CAUSAL ANALYSIS




Questions Regarding This Case?






Let's look at some Sample Extent of Injury Reports

We hope you
Have reviewed
these ahead of
this webinar.





Sample Report Analysis



DD - Dr. Kimble

What do you like about the format?

What is lacking?





Sample Report Analysis - DD - Dr. Kimble

What do you like about the format?

- ID data
- Purpose of the examination
- Location, start and stop time of exam
- List of records reviewed
- Reasonable medical exam*
- Attestations



Sample Report Analysis DD - Dr. Kimble

What is lacking?

- **On the surface, this report seems sufficient.**
- It is not until you read the RME report that you see clearly that the DD missed **MANY** important facts in the case.
- The DD mostly relied upon the claimant's history and did not verify from the records or include excerpts from the records, despite stating that the records were reviewed.
- **These FACT ERRORS discredit the report.**



Sample Report Analysis DD - Dr. Kimble

What is lacking?

- Mechanism vague – inconsistent with records
- No details of timeline of **complaints** from the records to determine MMI / IR / EOI
- No details of timeline of **clinical findings** from the records to determine MMI / IR / EOI
- Did not discuss the **imaging findings** in question nor how they may have or have not correlated with complaints and clinical findings
- Minimal to no discussion of **response** to treatments.



Sample Report Analysis - DD - Dr. Kimble

What is lacking?

- **The DDs Forensic Exam was limited at best**
- No provocative maneuvers of spine, SI joint / pelvis, hips or other lower extremity joints to evaluate for alternate explanations.
- No thigh circumference.
- Did not note location of calf circumferences, therefore, we don't know if they were even measured at the same location on both calves.



Sample Report Analysis DD - Dr. Kimble

What is lacking for EOI? (*continued*)

- Did not list the disputed diagnoses provided in the POD.
- **The Presiding Officer Directive instructed the DD to address MMI, IR and Extent of injury and to provide multiple certifications**
- Gave only one certification for MMI and IR, rather than at least the two necessary
 - One for conditions noted as carrier accepted;
 - Another for carrier accepted plus all conditions noted as disputed/additional claimed)
 - If the POD requested the D opinion., that could be a 3rd certification

Sample Report Analysis- DD - Dr. Kimble

What is lacking for EOI? (*continued*)


- Did not DEFINE the injury / diagnosis / condition(s) in question
- The EOI explanation was CONCLUSORY – **gave a conclusion without analysis of:**
 - MOI + Complaints / Clinical + Imaging + EBM

Sample Report Analysis - DD - Dr. Kimble

What is lacking for MMI / IR? (continued)

- Did not use Evidence Based Medicine to support opinions
- Did not tie the MMI date back to case specific details from the records on that date. Therefore unable to see if that MMI date is reasonable and medically probable.
- No knowledge as to clinical condition of the claimant on the MMI date chosen for determination of IR.
- **FATAL ERROR:** Used the MDG for determination of MMI rather than ODG.

Sample Report Analysis



RME - Dr. Wisdom

What do you like about the format?

What is lacking?



Sample Report Analysis - RME / Dr. Wisdom

What do you like about the format?

- A complete listing of the POD information
- A more accurate mechanism supplemented with information in the records
- An actual chronology of the records documenting the timing of complaints and clinical findings
- Points out the inconsistencies in the record that the DD failed to discuss



Sample Report Analysis - RME / Dr. Wisdom

What do you like about the format?


- **Defined** each of the additional claimed injury / conditions
- Gave **evidence-based medicine** to support opinions regarding **EOI**
- Gave clear direction from the **ODG** based on DX's considering, as to date of **MMI**
- Gave clear direction from **AMA Guides** as to **IR**
- Clear as to **which certification** the doctor was of the opinion was compensable

Sample Report Analysis Sample Report Analysis - RME / Dr. Wisdom

What is lacking?

Anything else you would have said?

Questions?



Weigh the evidence!

Top Ten Least Effective Things Stated in a DD Report

10. Reference to the injured employee as a “malingerer” or “social ingrate.”
9. Stating the injured employee fell to explain the mechanism of injury, when, he was hit by a bus.
8. “I wasn’t actually in the room when the injured employee was examined, but eating lunch in the adjacent break room, and I could hear everything he said.”

Top Ten Least Effective Things Stated in a DD Report

7. “He’s not yet at MMI, but I gave him an IR of 15% anyway because I felt sorry for him.”
6. Stating in your report, “because I said so.”
5. Citing diagnosis codes for all injuries in Extent of Injury, along with the sole statement “Looks right to me.”
4. After listing the injuries in Box 32c of the DWC-32 or listed in the POD, stating “Ain’t nobody got time for that.”

Top Ten Least Effective Things Stated in a DD Report

3. Referencing that you reviewed the medical records, “after the DD exam.”
2. Stating you solely relied upon the MDG in determining MMI/IR and Extent of Injury.
1. Stating in your narrative regarding causation, “No explanation required.”

EOI - REMEMBER:

- **YOU are the forensic expert for TDI-DWC**
- **Make your opinion thorough and explain it in a manner that laypeople can understand**
- **Provide evidence based medicine that supports your opinion.**
- **Ensure that the forms associated with your report convey the information in the narrative**



MMI/IR/Extent Of Injury (MMI/IR/EOI)

Changes to the **§127.1-127.25** and **§180.23** rules are effective 6/5/2023 and can be viewed at:

<https://www.tdi.texas.gov//wc/rules/2023rules.html>

Thank you.