

Designated Doctor Extent of Injury (EOI) Webinar Pre-course Sample Cases

Review the attached sample reports created for discussion during the Part II EOI Webinar.

1. DD Report of Dr. Dooright – This is a sample designated doctor report for Case #1 in the Part II webinar.
2. DD report Dr. Kimble
3. RME report Dr. Wisdom
4. DD report Dr. Pain

Review the reports and think about what could have been done better? What was done well? What questions do you have?

Darryl Dooright, M.D.
MEDICAL EXPERTS, INC
DESIGNATED DOCTOR EXAMINATION

Employee: John Smith

DOI: 02/14/2023

DWC No: 21321222

Insurance Carrier: ACME insurance

Carrier No: 9658172

Employer: Trucking Masters

Exam Date: 07/01/2023

Time In: 11:55 am Time Out: 12:58 pm*

**Does not include time to review records and medical decision making*

Exam Location: 2.14 Infinity and Beyond Trail, Austin, Texas 78750

Diagnoses: At least left knee strain, left knee contusion occurred per review of the medical records.

Disputed/Additional Claimed Diagnoses: Severe medial and moderate patellofemoral compartment osteoarthritis, Maceration / complex tear of the medial meniscus with extrusion of the body and involvement of the posterior root, High grade partial if not complete tear of the tibial attachment of the ACL, Lateral compartment chondromalacia without overt osteoarthritis, Small joint effusion.

PURPOSE OF THE EXAMINATION:

I have been requested to evaluate the above-named claimant for a designated doctor examination for the following purposes as per the DWC 32:

Extent of the Compensable Injury

I am a certified Designated Doctor in good standing with the Texas Department of Insurance – Division of Worker’s Compensation (TDI – DWC) but am not the DD for this claim. I have no disqualifying associations (one that may reasonably be perceived as having potential to influence my conduct or decision) and do not participate in any worker’s compensation networks. I counseled the claimant as to my role as Designated Doctor. The claimant was counseled that no doctor – patient relationship would exist as a result of this evaluation. I must base all opinions on reasonable medical probability and Texas adopted authoritative guidelines.

RECORDS REVIEWED INCLUDED: The following is the list of medical records that I was provided by the insurance carrier and treating doctor. I attest that I have reviewed all the medical records listed as required by rule 127.10(b). I will reference and give details from the records that are of significance and are most pertinent to my decision-making process.

Paginated Medical Records

Fast Medical Center (FMC) – Dr. Zippy - 06/26/2012, 07/11/2012, 07/30/2012, 08/06/2012 and 08/06/2012

Supreme Imaging - MRI Left Knee – 08/07/2012.

Dr. Bonebreaker – 08/22/2012, 09/07/2012, 09/14/2012 and 11/07/2012.

Dr. Bonebreaker - Operative Report 08/30/2012

Designated Doctor Examination / Dr. Benitez – 12/11/2012 (for DOI 06/26/09)

Employers First Report of Injury or Illness – 02/14/2023

Pretty Darn QUICK Urgent Care (PDQUC) / Dr. Rush – 02/28/2023, 03/24/2023

Pretty Darn QUICK Urgent Care (PDQUC) Physical Therapy – 03/02/2023

Supreme Imaging - MRI Left Knee – 04/05/2023.

Jim Cutter MD– 04/14/2023, 05/10/2023

Peer Review Inc – Sara Denial MD- 04/28/2023

PLN-11

Acme Insurance - Notice of Disputed Issues and Refusal to Pay Benefits –05/04/2023.

Jim Cutter MD - Causation Letter – 06/15/2023

Supreme Imaging – Weight bearing X-rays of bilateral knees – 07/05/2023.

Carrier Medical TimelineDWC-32 – 06/01/2023 OA 32-A – 06/15/2023

MECHANISM / HISTORY OF INJURY:

John Smith is a 55-year-old male with a reported date of injury of 2/14/2023. The IE reported that he slipped coming out of 18-wheeler, twisting his left knee, jamming it on the ground, at which point his knee buckled and twisted again, which caused him to fall on the left knee without being able to break fall.

CURRENT COMPLAINT:

When asked where he first experienced his pain on the date of injury (DOI), he pointed to an area across the left patellar tendon and just lateral to that. He then reported that there was immediate pain everywhere and the swelling was “massive”. He underwent physical therapy and felt that he worsened over time. He can barely walk. Nothing has helped, including an injection Dr. Pain administered on their second visit.

TREATMENT HISTORY / CHRONOLOGY OF RECORDS:

06/26/2012 – Prior Date of injury for LEFT knee.

06/28/06 – FAST Medical Centers (FMC) / Dr. Zippy: This was for date of injury of 06/26/09. The IE slipped on a wet floor and torqued his left leg. He experienced left knee pain with walking, standing and stepping up and down. On examination his knee had full ROM and no instability was noted. He walked with a slight limp. There was no swelling and slight tenderness noted in the record, though not the location. X-rays of the knee were “*negative*”. The assessment was knee strain. He was given restricted duty and was to start on PT.

Additional dates of service without improvement were on 07/11/2012, 07/30/2012 and 08/06/2012. Pain was variable as to anterior, medial or lateral. By the last DOS, knee ROM was limited. The doctor planned on an MRI.

08/07/2012 – Supreme Radiology - Left Knee MRI: Imaging demonstrated the ligaments were intact. There was high grade chondromalacia under the patella. The femoral and tibial medial compartment had subtle subchondral edema, subchondral cyst formation. There was a cyst in the anterior aspect of the medial meniscus and there were horizontal signal changes in the posterior horn of the medial meniscus.

08/10/2012 - FMC / Dr. Zippy: This record documented symptoms were stable and there was no improvement on that date. Gait was normal and the knee was stable. He was referred to ortho for the MRI findings.

08/22/2012 – Dr. Bonebreaker: Dr. Bonebreaker reported a history of “*catching, locking and giving way*”. On examination he had “*moderate to severe patellofemoral crepitus, positive patella grind, patellar slide and positive McMurray’s*”. He stated the MRI documented a “medial meniscus tear”. Arthroscopy was recommended.

08/30/2012 – Dr. Bonebreaker - Operative Report: This was a left knee arthroscopy. Procedures completed were a partial medial meniscectomy, removal of meniscal cyst and a hypertrophic plica. Severe grade III chondromalacia was noted over the entire weight bearing surface of the medial femoral condyle. There were “multiple large cracks and fissures of the medial tibial plateau” as per Dr. Bonebreak. Grade II changes at the trochlea. Chondroplasties of the patella and medial femoral condyle were performed.

09/07/2012 – Dr. Bonebreaker: Initial post op eval was benign and limited. He was put into PT. PT was 10 sessions over 8 weeks. Additional visit with Dr. Bone break were **09/14/2012** and **11/07/2012**. On the last date of service, he was released to return to work without restrictions.

012/11/09 - Designated Doctor Examination / Dr. Benitez: This DD examination was to address MMI and IR. This documented the IE had stepped off a forklift onto a wet floor and twisted his left knee. He was 44 years old and had a high school education. His job involved using forklifts and loading trucks. He had returned to work after the work-related injury. He reported “*Stairs gave him the worst problems*”.

On examination he had significant medial patellar tenderness. No instability was noted. McMurray’s was negative. There was slight swelling and slight effusion noted on that date. 1 cm of swelling was noted in the left knee. Strength was normal. **ROM was from -5 to 100 degrees in the left knee** and 0 to 145 degrees in the right knee. No atrophy was noted. The DD opined the IE was at MMI as of the date of the exam. He was given a 1% IR for a partial medial meniscectomy.

02/14/2023 - Current Date of Injury

02/14/2023 - Employers First Report of Injury or Illness: This documented a date of injury of 05/30/2023. The injury was documented as a pain in the left knee, outer front after “***slipping and falling on the anterolateral knee***”.

02/28/2023 - Pretty Darn QUICK Urgent Care (PDQUC) / Dr. Rush: He presented for pain in his left knee. A trip and fall mechanism on gravel was reported, causing him to land on his knee. His knee had crepitation and hurt to climb stairs. He had anterior and anterolateral pain. Over time, his knee felt stiff and pain was more global. He had no bruising initially. Swelling occurred over the first week. There were no complaints of instability or mechanical symptoms. He reported he “*never had right or left knee pain before*”. Some initial left forearm pain and bruising resolved.

He reported the history of knee surgery 10 - 11 years ago, “*meniscus and scraped arthritis*”, but also DDD/ spinal stenosis, prior knee, back and elbow surgeries. His BMI was noted to be over 45. He had sleep apnea, hypertension and diabetes.

He was walking with an antalgic gait without crutches. The left knee had a well healed surgical scar consistent with prior scope portals. The left knee was in varus. There were palpable hypertrophic changes

of the joint line medially > laterally. There was no warmth, but minor soft tissue swelling vs effusion of the left knee. He was tender at the anterolateral knee, including patellofemoral region, with no tenderness of the left forearm.

Knee ranges of motion were reported as ~ 0 to 120. Mostly limited by leg girths. Provocative testing difficult by BMI, but no obvious laxity with AP drawer or Varus / Valgus stress

Left knee x-ray (non-weightbearing) demonstrated tricompartmental degenerative changes of mainly the medial joint line and patellofemoral articulation.

The diagnosis was "*left knee strain and left knee contusion*". The plan was for PT. The IE was already taking hydromorphone for back pain. Restricted duty of no climbing was recommended.

03/02/2023 - Pretty Darn QUICK Urgent Care (PDQUC) / - Physical Therapy: The IE had left knee pain. His history of multiple comorbidities was noted.

On examination left knee ROM was -5 to 105. [[This ROM was consistent with the ROM he demonstrated at MMI in 2012.](#)] Strength was 4/5 in the muscles crossing the knee. Stability tests were normal. The assessment was "possible" left medial meniscus involvement. The plan was for PT three times a week for four weeks. There were 8 additional treatments.

03/24/17 – PDQUC – Dr. Rush: After initial improvement, ROM had declined to flexion 60 from the 101 in PT. He was to continue PT and he would order an MRI of the knee. The IE was kept on restrictions.

04/05/2023 – Supreme Imaging - MRI Left Knee: Indications were "knee pain". Imaging demonstrated:

1. Severe medial and moderate patellofemoral compartment osteoarthritis.
2. There was maceration / complex tear of the medial meniscus with extrusion of the body and involvement of the posterior root.
3. High grade partial if not complete tear of the tibial attachment of the ACL.
4. Lateral compartment chondromalacia without overt osteoarthritis.
5. Small joint effusion.
6. No bone contusion at the anterolateral tibiofemoral compartment or patellofemoral compartment.
7. No bone contusions of the anterior tibia or posterior femur.

04/07/2023 – PSGUC – Dr. Rush. After review of the MRI, Dr. Rush referred the IE to an orthopedic surgeon.

04/14/2023 – Jim Cutter MD: Dr. Rush referred Mr. Smith to Dr. Cutter for an orthopedic evaluation. This documented the pain began after he "*twisted his knee as he fell out of his 18 wheeler*". He had pain in his medial, lateral and anterior knee, rated as 6/10. His medical history included hypertension, arthritis, snoring, heartburn, back pain, headaches, numbness, weakness, excess fatigue and easy bruising. Medications at that time were hydromorphone, started on 10/02/16.

Exam of the left knee demonstrated a moderate joint effusion. (+) McMurray's medial > lateral. (+) Lachman's and Anterior Drawer. His impression was: Torn Meniscus AND arthritis. His plan was to

consider and injection but recommended a Total Knee Arthroplasty

04/28/2023 – Peer Review Inc – Sara Denial MD: The records were reviewed, and the history was summarized by the Peer Review doctor. She presented evidence-based medicine regarding degenerative knee arthritis, meniscal tears and risk factors for progression.

“The MOI was not consistent with causing or producing the ACL tear. The osteoarthritis and the meniscal changes are degenerative and there is no evidence on exam or imaging that there was aggravation”.

05/04/2023 – PLN-11: Acme Insurance - Notice of Disputed Issues and Refusal to Pay Benefits:
“The carrier disputes that any of the findings on the MRI were caused or aggravated by the events of 02/14/2023”.

05/10/2023 – Jim Cutter, MD: Dr. Cutter received the PLN-11. There was no change in the initial history or exam he documented. He provided a steroid injection in the left knee.

05/15/2023 – Jim Cutter MD - Causation Letter: In Dr. Cutter’s letter of causation, he opined the IE had *“sustained an injury to include a complex tear of the medial meniscus, unilateral primary osteoarthritis, a patellofemoral disorder and a sprain of the ACL secondary to twisting, torquing and direct impact to the left knee while getting out of an eighteen-wheeler”.*

MEDICAL HISTORY:

Conditions: 1. BMI over 45, 2. Sleep apnea, 3. Hypertension, 4. Diabetes

Surgeries: 1. Knee surgery 10 - 11 years ago, *“meniscus and scraped arthritis”*, 2. Spine surgery for spinal stenosis, 3. Right shoulder surgery 2021

Prior Injuries: 1. Left knee WC injury 10 – 11 years ago, 2. Football injury left knee in the late 70s, 3. Denies prior right knee injuries.

Medications: 1. Oxycodone for prior back injury, since 10/02/16, 2. Verapamil for BP

SOCIAL and OCCUPATIONAL HISTORY:

Mr. Smith is high school educated with some college. He is never married and lives with his sister.

He had been with this employer or over 15 years. His job is in the warehouse as a supervisor but occasionally drives a forklift or 18-wheeler in the warehouse / yard. His employer is trying to accommodate his restrictions.

REVIEW OF SYMPTOMS:

The multi-system Review of symptoms was pertinent for: Heartburn, back pain, headaches, numbness, weakness, excess fatigue and easy bruising.

PHYSICAL EXAMINATION:

Ht: 5'8"

Wt: 303 lbs

BP: 53/93

P: 79

Identified by his license. He was accompanied to the evaluation by his sister. After completing the history and making indirect observations, the IE changed into an exam gown and shorts. His movement patterns in the lobby and in the exam room were consistent with demonstrated movement patterns when formally measured.

His gait was wide based consistent with his body habitus. The unaffected right knee and affected left knee demonstrated varus in neutral stance, during gait and while in supine. He walked with more antalgia off the right leg. Functionally, he could perform bilateral squat to 45 degrees of knee and hip flexion with retropatellar crepitation bilaterally. He put more weight on the "affected" left leg. Significant difficulties with single limb balance for left and right legs. Single limb squat demonstrated more limitations than bilateral squat and with compensatory movements.

The lumbar spine a longitudinal 6 – 8 cm scar, above and below the L4-L5 level. The iliac crests palpated to be relatively level. There was no obvious spasm or significant muscular guarding present in the thoracolumbar spine. There were symmetrically decreased side bends without end range pain (ERP). Extension was more limited than flexion with ERP. Movement patterns were consistent with age and body habitus.

Distracted SLR in seated and supine SLR did not reproduce dural tension signs. FABER and FADIR test were accomplished with difficulty due to body habitus but did not cause pain referral to the knee. Attempted femoral nerve stretch tests were positive for significant bilateral hip flexor tightness, but no femoral nerve stretch signs. The left knee had a well healed surgical scar consistent with prior scope portals. The right knee was in varus and had obvious bony hypertrophic changes of the joint line mostly medial. The left knee had similar appearance. There is no erythema or warmth to either knee. Both knees had a degree of soft tissue swelling, but no significant suprapatellar effusion compared to the left

Knee ranges of motion were checked with handheld inclinometers as per recommended positions in the AMA Guides, 4th Edition.

RIGHT: Flexion to 115 degrees with ~ 3 degrees with lack of extension.

LEFT: Flexion to 118. There is no evidence of an extension lag. There is no evidence of a flexioncontracture.

Passive ROMS were consistent with active ROM.

Vascular: His distal limb vascular exam was normal. Pulses were symmetric, there was good capillary refill and normal temperature. There were no dystrophic skin or nail changes. There were no varicosities.

Leg circumferences: as per AMA recommendations:

Calves were measured at 12 cm below the patella (where circumference greatest on the right).

Right 48.5 cm and left 48.5 cm.

Thighs were measured 10 cm above the patella. Right 72 and left 71.5.

Reflexes: Bilateral patella were 2/4 symmetric.
The medial hamstrings were trace present but symmetric.
The achilles reflexes were absent.

Sensory: There are no obvious sensory deficits in a significant dermatomal or peripheral nerve distribution in either lower extremity.

Motor: Manual muscle testing also revealed good intact strength in major muscle groups of proximal and distal bilateral lower extremities.

Provocative Maneuvers: Based on his thigh circumferences and inflexibilities, it was difficult to perform an adequate McMurray's Test.

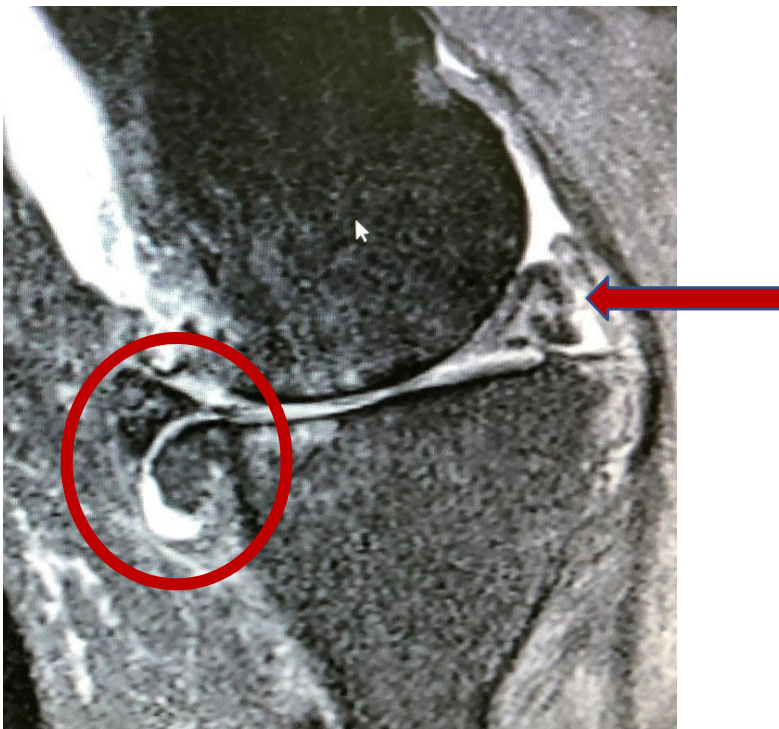Right Knee(uninjured): Anterior Drawer = couple of mm of translation but with a good endpoint. Lachman's Test = stable. Varus and Valgus Stress at 0 degrees was stable. Valgus Stress at 30 degrees of flexion demonstrated some increased joint line opening with end range mechanical click.

Left Knee (injured): Anterior drawer = ~ 3 mm with a good endpoint. Posterior Drawer = negative. Varus and Valgus Stress at 0 degrees were very stable. Varus Stress at 30 degrees with mild joint line opening but with a fair to good endpoint and no complaints of pain or instability.

IMAGING REVIEW:

Copies of the MRI imaging were available for review and thumbnails are incorporated into the report.

Sagittal Image of MRI of John Smith from 04/05/2023: Medial paramidline. Anterior is on the left and posterior is on the right.

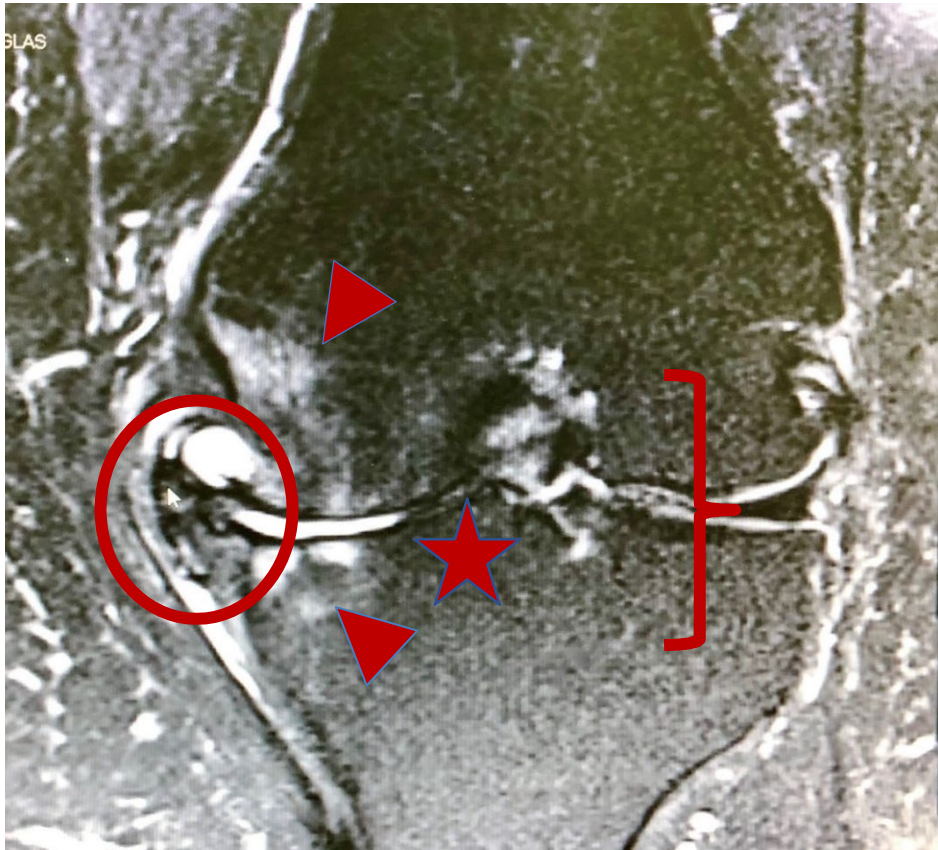





= Complex tear of posterior horn of medial meniscus

The medial compartment sagittal images also demonstrate that the medial meniscus was very macerated and extruded anteriorly and a large osteophyte coming off the posterior aspect of the medial femoral

condyle.

Coronal Image of MRI of John Smith from 04/05/2023: The lateral compartment is on the right and the medial compartment is on the left. Note the remodeling of the medial tibial plateau > medial femoral condyle compared to the normal appearing lateral medial plateau and femoral condyle. The medial meniscus is extruded and there are osteophytic growths encapsulating the meniscus.



-  = Medial Femoral Condyle and Medial Tibial Plateau/reactive subchondral changes
-  = Extruded Medial meniscus osteophyte complex
-  = Notch
-  = Bone on bone loss of chondral cartilage at the lateral medial compartment near the notch

10/05/2023 – Supreme Imaging – X-rays of the lower extremity. I ordered bilateral AP views of the knee ordered and obtained as per AMA recommendations to be completed in weightbearing with the beam 36 inches from the knee and parallel to the articular surface.

The purpose of these images was to determine the alignment of the native right knee and the injured knee on the left and the radiographic cartilage interval of the asymptomatic knee.

Findings were:

- **Left knee** (affected knee): This demonstrated Severe OA changes in the medial tibiofemoral and patellofemoral compartments.
- **Right knee** (unaffected): This also demonstrated **severe OA changes** in the medial tibiofemoral compartment and patellofemoral compartments. There was a moderate degree of OA change compared to imaging completed two years prior on 10/09/18.

EVIDENCE BASED MEDICINE:

The meniscus is the cartilage shock absorber between the femur and the tibia that also provides stability to the knee joint. **Degenerative** tears or signal changes are the most common tears or changes seen in all ages of patients. A common type of **complex tear** has components of horizontal and radial tears. As per Ruben et al, *“Nearly all of these are degenerative in origin.*

According to Englund, *“When meniscal tears are found, it is commonly assumed that the symptoms are attributable to them.”* Based on many studies by Englund and others in the reference list, there is a high prevalence of meniscal pathology in the asymptomatic population and is more common the older the individual and with male gender. Like with any degenerative finding within a body region noted on MRI, it is recommended that there be clinical correlation with the mechanism of injury and physical examination, rather than interpreting any "positive" finding as due to a specific incident. It is also notable that in a study by Liu et al. *“patients older than 40 years with unilateral occupational claims for new shoulder and knee symptoms have bilateral MRI changes”*. While we do not have bilateral MRIs in this case, we have x-rays that verify that there are same or even worse radiographic appearance of the uninjured right knee.

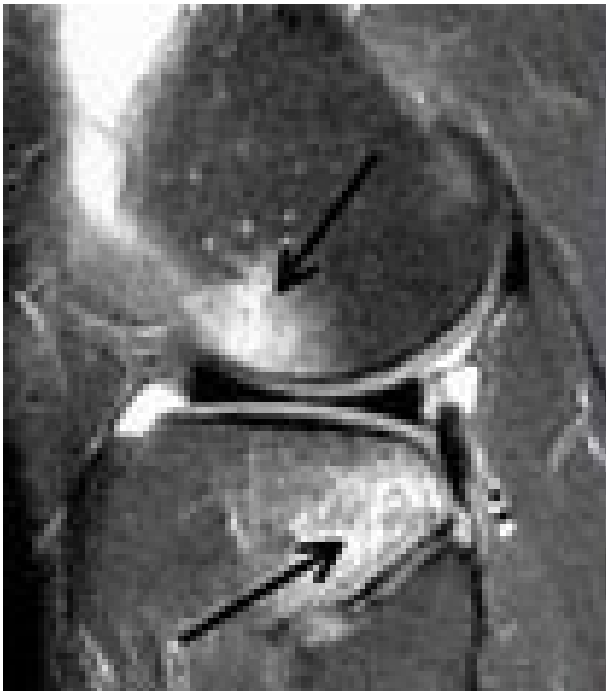
Degenerative changes can also occur to the chondral or hyaline cartilage that covers the end of the tibia and femur. As this thins, it is called chondromalacia. As the subchondral bone reacts to this degenerative thinning, bone spurs are formed. Once joint space narrowing and osteophytes are visible on x-ray, it is called osteoarthritis and can be graded. Chondral cartilage changes, osteoarthritis and meniscal attrition go hand in hand as part of the degenerative process.

The ACL is a primary ligament restraint that limits the tibia from translating forward beneath the femur. Acute injuries often result in significant bloody effusions with hours that can persist for many weeks. Primary signs of an acute ACL injury on an MRI could also be increased signal on T2 and fat saturated proton density images, fiber discontinuity and abnormal anterior cruciate ligament orientation relative to the intercondylar line. When there is a twisting pivot shift type mechanism that results in a posterior horn medial meniscus tear, secondary signs are bone contusions in the lateral femoral condyle and posterior tibial plateau or acute bone injury on the MRI equivalent to the x-ray findings of a deep lateral sulcus sign. The presence of bone bruising at the posterolateral tibial plateau had approximately 50% sensitivity and 97% specificity for associated ACL tear by the two reviewers in the study by McCauley et al. [\[Figure3.\]](#)

We typically think of the ACL as a tissue that is only torn acutely. The EBM related to degenerative arthritis demonstrates is not true. A study Stein et al found that between 22 and 35 % of those with

symptomatic knee OA have *“incidental complete anterior cruciate ligament (ACL) tears identified by magnetic resonance imaging (MRI). The majority of persons with this finding have no recollection of prior trauma or substantive knee injury likely to predispose to ACL tear”*. In the study by Wada et al, osteophyte growth in the notch area appears to correlate with progression of medial tibiofemoral knee OA. Additionally, Wada *et al.* observed the intercondylar notch areas with more severe OA had a significantly smaller notch width than those with milder OA or normal knees. This was correlated with ACL tears in the osteoarthritic knees. Lastly, the findings of Leon et al proposed that intercondylar notch stenosis may be a *“proximate cause of ACL damage, symptomatic instability and loss of extension in participants with knee OA”*.

Figure 3: “Kissing lesions” from Pivot shift mechanism in ACUTE ACL TEARS. Not THIS claim.



From [Radiopaedia](#) – Anterior Cruciate Ligament Tear

DIAGNOSES:

Left knee strain, left knee contusion resulted from the injury based on review of the medical records and certifying examination.

Disputed/Additional Claimed Diagnoses: Severe medial and moderate patellofemoral compartment osteoarthritis, Maceration / complex tear of the medial meniscus with extrusion of the body and involvement of the posterior root, High grade partial if not complete tear of the tibial attachment of the ACL, Lateral compartment chondromalacia without overt osteoarthritis, Small joint effusion.

EXTENT OF INJURY:

The question for consideration regarding Extent of Injury is whether the accident or incident giving rise to the compensable injury is a substantial factor in bringing about the additional claimed injuries or conditions, and without it, the additional injuries or conditions would not have occurred? Injury is damage or harm to the physical structure of the body and a disease or infection naturally resulting from the damage or harm and could include occupational disease. **Aggravation** in the

context of a pre-existing injury should demonstrate additional damage or harm to the physical structure of the body, as evidenced by an enhancement, acceleration or worsening of an underlying condition.

The additional claimed injuries in this claim were severe medial and moderate patellofemoral compartment osteoarthritis, Maceration / complex tear of the medial meniscus with extrusion of the body and involvement of the posterior root, High grade partial if not complete tear of the tibial attachment of the ACL, Lateral compartment chondromalacia without overt osteoarthritis, Small joint effusion, No bone contusion at the anterolateral tibiofemoral compartment or patellofemoral compartment. And No bone contusions of the anterior tibia or posterior femur.

All findings are present on MRI imaging that was obtained within 6 weeks of the DOI. After review of the imaging in this claim and review of the concurrent weightbearing xrays of both knees, it is clear that the osteoarthritis, the medical meniscal changes and the changes to the ACL are ALL degenerative in nature. I must however consider if there was evidence of aggravation. First, the imaging findings do not demonstrate objective evidence of additional injury or harm. There is no edema in the tissues in the intercondylar notch. There are no kissing lesions. There was no large hemorrhagic effusion that one would expect if the ACL tear was acute. There was not even a bone contusion of the patellofemoral articulation as one could possibly sustain with a fall on to the anterior knee.

I considered the mechanism. The most credible mechanism was that from the First report of injury and the first contact with a physician on 02/28/2023. A trip and fall mechanism on gravel was reported, causing him to land on his knee. This did not change until he presented to the orthopedist, where a twisting mechanism was noted. By the time the Peer physician pointed out the inconsistency of the mechanism for the findings on the MRI, the MOI that the IE related to me today is quite dramatic and inconsistent. A trip and fall onto the knee are most consistent with allow grade strain of the muscles around the knee and a contusion form the direct blow / fall. This mechanism would not be expected to cause or aggravate weight bearing OA, a degenerative meniscus or chronic ACL insufficiency in absence of other imaging or other objective clinical findings.

If we address the timeline of symptoms and findings, they were initially most consistent with the initial proposed injury diagnoses of a strain and contusion. Symptoms and findings worsened over time, rather than being at their worst 2 weeks after the DOI. The orthopedist found many clinical findings that were inconsistent with the initial MD eval, initial PT eval and my certifying examination. We also know that the ROM at the evaluation of the PT shortly after the DOI was consistent with the ROM for the DD that evaluated the IE for a years earlier DOI. The likely explanation for lack of instability despite chronic ACL and meniscal insufficiency is the significant osteophytic spurring that afford stability.

The evidence-based medicine was already discussed and most if not all of what was discussed was applicable in this claim.

It is my opinion based on my education and training, review and analysis of the records (mechanism, timing of complaints and clinical findings), review of the post-injury imaging in this case, examination of the IE and application of evidenced based medicine and the analysis provided above, AND with a degree of **reasonable medical probability** that the events of the DOI **WERE NOT a substantial factor in producing or aggravating:**

Severe medial and moderate patellofemoral compartment osteoarthritis, Maceration /complex tear of the medial meniscus with extrusion of the body and involvement of the posterior root, High grade partial if not complete tear of the tibial attachment of the ACL, Lateral compartment chondromalacia without overt osteoarthritis, Small joint effusion.

*All opinions rendered are based on reasonable medical probability. This opinion is based on a thorough review of the records or documentation cited, and my clinical assessment and examination. My opinion relied upon the AMA Guides {IR} Official Disability Guidelines {MMI}, as well as Evidence Based Medicine (EBM) available and generally accepted standards of medical practice recognized in the medical community that are relied upon in addressing the issues for which the injury includes. **Evidence-based medicine**" means the use of current best quality scientific and medical evidence formulated from credible scientific studies, including peer-reviewed medical literature and other current scientifically based texts, and treatment and practice guidelines in making decisions about the care of individual patients. If more information becomes available at a later date, an additional report / service / reconsideration may be requested. Such information may or may not change the opinions rendered in this evaluation. This opinion does not constitute recommendations for specific claims or administrative functions to be made or enforced.*

Darryl Dooright, M.D.

American Board of Physical Medicine and Rehabilitation
Texas License # H9525

This report was reviewed and approved in its final form and attested to by my original and electronic signature.

ATTACHMENTS: DWC-69 Exam Worksheets x 3 ARA Imaging report
Cc TDI - DWC (Fax: 512-490-1047)
CME Ins. Co. attn: Brett Cook (Fax: 512-222- 2621)
Victor Rush MD – Treating Doctor (Fax: 512-320-3002)
John Smith (Certified Mail: 7018309000044646242; 2222 Loopy trail, Egypt, Texas)

REFERENCES:

[Anterior Cruciate Ligament \(ACL\) MRI - Medscape Reference](https://emedicine.medscape.com › 400547-overview) <https://emedicine.medscape.com › 400547-overview>
Allen AM et al. Chew FS (Ed). Updated July 8, 2021

Cippola M, Scala A, Gianni E, Puddu G. **Different patterns of meniscal tears in acute anterior cruciate ligament (ACL) ruptures and in chronic ACL-deficient knees. Classification, staging and timing of treatment.** Knee Surg Sports Traumatol Arthrosc. 1995;3(3):130-4. doi: 10.1007/BF01565470.

Englund M. **The Role of the Meniscus in Osteoarthritis Genesis.** Rheumatic Disease Clinics of North America. 2008;34(3):573–579.

Filardo G, Andriolo L, di Laura Frattura G, Napoli, Zaffagnini S, Candrian C. **Bone bruise in anterior cruciate ligament rupture entails a more severe joint damage affecting joint degenerative progression.** Knee Surg Sports Traumatol Arthrosc. 2019 Jan;27(1):44-59. doi: 10.1007/s00167-018-4993-4. PMID: 29869683;

McCauley T R, Moses M, Kier R, Lynch J K, Barton J W, Jokl P. **MRI Diagnosis of Tears of Anterior Cruciate Ligament of the Knee; Importance of Ancillary Findings.** AJR AM J Roentgel. 1994 Jan; 162(1): 115-9.

Radiopaedia – Anterior Cruciate Ligament Tear

Yoon KH, Yoo JH, Kim KI. **Bone contusion and associated meniscal and medial collateral ligament injury in patients with anterior cruciate ligament rupture.** J Bone Joint Surg Am. 2011 Aug 17;93(16):1510-8. doi: 10.2106/JBJS.J.01320. PMID: 22204006

12/27/22 Operative Report ABC Hospital / James Kildare, MD

01/15–03/15/23 Post-op PT notes (14 visits) Mark Pullham, DPT

History of Present Injury: Ms. Doe is a 44-year old female who has been employed as a nurse at XYZ County Charity Hospital District since 2001. The claimant reported to me that on August 25, 2022, she was restraining a combative patient by herself. She had to wrestle and struggle with the patient and repeatedly perform “takedown” maneuvers. Afterwards she felt pain in her low back, which she reported then spread into her right leg.

Current Complaints: The claimant had lumbar surgery on 12/27/22. She is 96 days post op at the time of this examination. She currently complains of pain and stiffness in her low back. She also says that her right leg pain has improved since surgery, but that she still has pain in her lower back and right buttock that is worsened with sitting, bending forward, lifting, coughing, and sneezing.

Her pain level is 5/10. Her Oswestry score is 43%. She was released by her surgeon, Dr. Kildare, and she returned to work on 03/04/23.

Return to work: Returned to work without restriction 03/04/23.

Current Medications and Treatment: Medications: The examinee does not receive any medication for her back other than OTC ibuprofen pm.

Past Medical History: C-section 1991. Family History: Parents are both deceased, mother had CVA at age 74 and father had an MI at age 72.

Social History: The examinee is married and has three children, 25 to 34 years of age. She does not smoke tobacco. She drinks socially having approximately one drink a week.

Surgeries: Bilateral tubal ligation, tonsillectomy, and adenoidectomy, left knee surgery and cholecystectomy.

Prior Treatment: Ms. Doe received treatment consisting of rest, prescription medication, physical therapy prior to surgery, lumbar surgery, and post-operative physical therapy. She is not currently receiving treatment for this injury other than continuing her exercise program at home and Jim’s Gym. She takes OTC ibuprofen as needed.

Physical Examination:

The injured employee was observed entering the examination office. She walked slowly with a careful gait without assistance. She used the handrail while coming up from one flight of stairs. She is alert, oriented, a good historian and cooperative to testing procedures. There are no signs of symptom magnification or inappropriate illness behavior. She shifted her weight occasionally while sitting. She did tripod while sitting on the examination table and with sit to stand transition (positive Minor’s sign). On inspection, the lumbar spine had a 2 cm midline surgical scar at L4/5. There was no other deformity and there was no lumbar list.

Lumbosacral ROM: Range of motion of the lumbar spine was measured today using bubble inclinometers according to the methods outlined in the *AMA Guides to the Evaluation of Permanent Impairment, 4th Ed.* The ROM was not used to determine IR but is a valid assessment of the condition of the lumbar spine.

Motion	Normal	Current ROM	Pain
--------	--------	-------------	------

Flexion	60	40	Low back pain, radiating to right buttock
Extension	25	15	Low back pain
L Lateral Flexion	25	10	Low back stiffness
R Lateral Flexion	25	5	Low back pain
R SLR	90	60	Low back pain, radiating R buttock
Left SLR	90	75	No pain

Neurological Evaluation:

The L3-S1 dermatomes had normal sensory perception bilaterally as tested with the Whartenburg pinwheel device. Patellar DTRs were 2+ bilaterally, Achilles DTRs were 1+ bilaterally.

Circumferential calf measurements were: right = 29 cm; left = 28 cm.

Manual muscle testing showed the hip flexors, quadriceps, hamstrings, gluteus medius, and tibialis anterior were 5/5 bilaterally. The right extensor hallicus longus was 4+/5.

Supine right SLR at 60 produced low back pain, radiating into the right buttock. Ankle dorsiflexion further increased the low back and right buttock pain. Left SLR was 75 degrees limited by hamstring tightness without evidence of neural tension.

SUMMARY AND COMMENTS

Diagnoses:

1. Lumbar sprain/strain S335.XXA / S39.012A
2. L4/5 herniated disc M5126
3. Right L5 radiculopathy M5416
4. Lumbar degenerative disc disease
5. Lumbar facet hypertrophy M1716

Issues Ordered to be Addressed:

Maximum Medical Improvement – Question: Has MMI been reached; if so, on what date (may not be greater than the statutory MMI date shown above)?

Answer: A request has been made to determine the date of Maximum Medical Improvement (MMI). DWC defines MMI as "the earliest date after which, based on reasonable medical probability, further material recovery from or lasting improvement to an injury can no longer reasonably be anticipated."

It is my opinion that the examinee has reached MMI and did so on March 21, 2023. The MDGuidelines show that a Nurse, General Duty (Medical Ser.) Alternate Titles: Nurse, Staff is in the "Medium" job classification per the US Department of Labor's Dictionary of Occupational Titles. The expected maximum disability duration for a lumbar sprain/strain Medium" job classification per the MDGuidelines is 42 days. However, Ms. Doe underwent an L4/5 laminotomy/microdiscectomy on 12/27/22 and the expected maximum disability duration for "surgical treatment, lumbar discectomy" for the "Medium" job classification per the

Richard Kimble, M.D., Designated Doctor Examination
Jane Doe, DWC No.: 12345678
April 4, 2023

MDGuidelines is 84 days after surgery, which is March 21, 2023. So she reached clinical MMI on March 21, 2023.

Impairment Rating – Question: As of the MMI date, what is the IR?

Answer: Ms. Doe has persistent symptoms in the L5 dermatome, neural tension signs, and weakness in the L5 myotome, all evidence of the right L5 radiculopathy for which she had surgery. Ms. Doe’s spine impairment is DRE impairment category III - Radiculopathy for the persistent complaints right L5 radiculopathy.

Extent of Injury – Question: Was the accident or incident giving rise to the compensable injury a substantial factor in bring about the additional claimed injuries or conditions, and without it, the additional injuries or conditions would not have occurred? (Include an explanation of the basis for your opinion)

Answer: The injuries (diagnosis/body parts/conditions) in question, claimed to be caused by, or naturally resulting from the accident or incident listed in the POD are:

1. L4-5 herniated disc
2. Right L5 radiculopathy
3. Lumbar degenerative disc disease
4. Lumbar facet hypertrophy.

The 08/25/2022 injury extends to the L4/5 herniated disc and right L5 radiculopathy. It does not extend to the lumbar degenerative disc disease or lumbar facet hypertrophy.

I find that the diagnoses of L4/5 herniated disc and right L5 radiculopathy are consistent with the mechanism of injury and are supported in a consistent fashion in the medical record.

The opinions rendered in this case are the opinions of this evaluator. This evaluation has been conducted on the basis of the medical examination and documentation that was provided, with the assumption that the material is true and correct. If more information becomes available at a later date, additional service/reports/reconsideration may be requested. Such information may or may not change the opinions rendered in this evaluation. This opinion is based on a clinical assessment, examination, and documentation. This opinion does not constitute per se the recommendation for specific claims or administrative functions to be made or enforced.

If I can be of additional service in this matter, please feel free to contact my office.

Sincerely,

Richard Kimble, M.D.
RK:aa/hhh

I reviewed and approved the final version of this report, as reflected by my signature below.

cc: Jane Doe

Jane Doe’s attorney

Insurance Carrier

Richard Kimble, M.D., Designated Doctor Examination
Jane Doe, DWC No.: 13456789
April 4, 2023

This report and attachments were sent to the parties as required by rule 127.10. on 4/8/201

11/07/2022	MRI lumbar spine w/o contrast (report and images reviewed)	Benjamin F. Pearce, MD
12/18/22	Peer review report	Anytown Neurology Associates, Greg House, MD
12/27/22	Operative Report	ABC Hospital, James James Kildare, MD
01/15/22-03/01/23	Physical Therapy notes	Mark Pullman DPT
12/14/22-04/3/23	Office notes	James Kildare, MD
03/12/23	Presiding Officer Directive (POD)	For Designated Doctor Exam
03/23/23	OA-32A	Commissioner's Order
03/26/23	Carrier Analysis Letter	Attorney for XYZ Hospital
04/04/23	Designated Doctor examination	Richard Kimble, MD
07/01/23	DWC-22	Required Medical Examination Order

CHIEF COMPLAINT:

Low back pain

HISTORY OF PRESENT ILLNESS/INJURY:

Ms. Doe was evaluated by me on 07/14/23. She is a 44-year-old Caucasian female who reports she injured her back while working as a nurse at XYZ County Hospital District when she restrained a violent patient in the psychiatric unit.

COMPLAINTS:

The injured employee (IE) complains of persistent low back pain. She reports that her back hurts on and off and it is clearly better now than initially. She does still have some limitations in her ability to bend and to walk for long distances. She performs all her own activities of daily living (ADLS). Every now and then she can experience some numbness on the dorsum of her foot.

As part of this evaluation, Ms. Doe completed a Symptom Diagram on 07/14/23, which shows right sided lower lumbar back pain extending into the right buttock, described as an "ache" by symbol. She rated this as a 3/10 and her Oswestry score also on 07/14/23 is 24%. Her back pain is worse with bending, and prolonged standing or sitting. The claimant had back surgery on 12/27/22. She has had 14 visits of 8 weeks of post-op therapy. She continues to take ibuprofen as needed and has returned to her job as a nurse.

RECORD REVIEW:

The IE was seen on 08/25/22, the reported date of the work-related injury, at the ER complaining of back pain. The 08/25/22 ER records report she *“tripped and fell yesterday and twisted her lower back”*. This mechanism is inconsistent with what was reported to me today. She also reported that *“The pain radiates to the **left** thigh”*. Straight leg raising was said to be positive at 30 degrees bilaterally. Back tenderness was reported. She had pain with extension more than flexion of the lumbar spine. (Worsening with extension rather than flexion is inconsistent with discogenic pain.). On that date, reflexes, sensation and strength were reported as normal. The claimant was diagnosed with a herniated disc in the ER (It is unclear how the diagnosis of a herniated lumbar intervertebral disc was made at the ER.)

Ms. Doe saw Yuri Zhivago on 08/30/22, and his record stated, *“presents with lumbar sprain/strain”*. The mechanism was reported as a trip and fall. The physical exam was limited to *“ROM of the spine is ok with moderate pain with certain motions”*. There was no mention of any lower extremity symptoms or neurologic findings. Treatment included oral and an IM injection of corticosteroids and referral to PMR.

The claimant had a lumbar MRI on 9/1/22, and the order for the MRI scan reported indications by the treating doctor of *“Lumbago with sciatica of the **left** side.”* Frank Burns MD reported the MRI scan showed multiple level degenerative disc disease especially at L4/5 and affecting the L3/4 level, with disc protrusions at both levels. There was also facet hypertrophy at the lowest 3 levels. The L3/L4 disc protrusion was central without central or lateral recess stenosis and the L4/5 disc protrusion was effacing the **right** lateral recess. This was opposite side of the claimant’s initial **left** thigh symptoms. **There was no nerve root impingement or evidence of acute findings as per the radiologist report or as per my review.**

EMG/NCS testing of the bilateral lower extremities was done on 9/10/22. The report from Jennifer Melfi, MD dated 9/23/22 did not show any electrodiagnostic evidence of radiculopathy.

Ms. Doe had 10 physical therapy visits in September 2012 and October 10th, 2022. **Her exam on the last day of therapy was benign with some residual complaints of mainly left sided LBP, but near full ROM and a normal neurologic examination.**

Ms. Doe saw Dr. Zhivago on 10/30/22. The notes states *“she was doing very well until 3 days ago when she sneezed and now, she is in a lot of pain and is having a hard time getting around.”* Dr. Zhivago also reported that *“her **right** leg is weak”* and *“has radiculopathy in the right L5-S1 dermatome.”* She was given another cortisone injection and another lumbar MRI scan was ordered.

The repeat MRI of the lumbar spine was performed on 11/7/2022. Dr. Burns again interpreted the images and reported there was an *“interval large disc herniation on the right at L4/L5 producing impingement of the right L5 nerve root”*.

Ms. Doe saw James Kildare, MD. He documented a "positive SLR" for right buttock pain. He did not record any clear neurologic deficits. He performed an L4/5 microdiscectomy and laminotomy on 12/27/22. She completed 14 visits of post-operative physical therapy. The last therapy note documented some persistent right sided LBP and a right distal L5 sensory loss, but no loss of L5 reflex and it was stated that there was no atrophy and no residual dural tension signs. She was released on 04/03/23 by Dr. Kildare to return as needed.

The claimant saw Richard Kimble, MD for a designated doctor evaluation on April 4, 2023. Dr. Kimble assigned MMI of March 21, 2023, citing the MD Guidelines disability duration following lumbar discectomy. He did not discuss the ODG or any case specific details as a determinant of the date of MMI. He assigned a 10% IR for DRE III for "*lumbar radiculopathy*". Dr. Kimble appears to have certified MMI and IR for an L4/5 disc herniation and right L5 radiculopathy in the one certification he provided. Dr. Kimble stated that the 08/25/2022 compensable injury included an L4/5 disc herniation and a right L5 radiculopathy, but the 8/25/2022 injury did not include lumbar degenerative disc disease or lumbar facet hypertrophy.

It is my opinion that Dr. Kimble's opinion was conclusory. He did not explain the basis of his opinions regarding the extent of Ms. Doe's injury, only stating that "*the L4/5 disc herniation and the lumbar radiculopathy are consistent with the mechanism of injury and supported in a consistent fashion in the medical record.*" He did not discuss the inconsistencies of this claim. He provided no discussion of the discrepancy of the mechanism, the difference between the two MRI imaging studies, nor the switch of presenting symptoms from the left side to the right side after a non-injury event. The DD provided no timeline of the complaints nor any clinical finding from the medical record that would support his opinion.

As part of this evaluation, Ms. Doe completed a pain drawing on 07/14/23, which shows right sided lower lumbar back pain extending into the right buttock, described as an "ache" by symbol. She rated this as a 3/10 and her Oswestry score also on 07/14/23 is 24%. Her back pain is worse with bending, and prolonged standing or sitting.

REVIEW OF SYSTEMS

CONSTITUTIONAL: No fevers, chills, sweats or unplanned weight changes.

EYES: No double or blurred vision or visual symptoms.

ENT: No difficulties with hearing or swallowing.

CARDIOVASCULAR: No chest pain, irregular heartbeats, sudden changes in heartbeat or palpitation, swollen legs or feet, heart murmurs, high blood pressure, cramps in her legs with walking, pain in her feet or toes at night or varicose veins.

RESPIRATORY: No dyspnea on exertion, no wheezing or cough.

GI: No nausea, vomiting, diarrhea, constipation, or abdominal pain.

GU: No urinary hesitancy or dribbling. No nocturia or urinary frequency. No abnormal urethral discharge. No sexual dysfunction. No saddle sensory loss.

MUSCULOSKELETAL: Low back pain from 08/25/22 injury.

NEUROLOGIC: No chronic headaches, seizures, loss of consciousness or dizziness. Patient denies numbness, tingling or weakness.

PSYCHIATRIC: No problems with mood disturbance, anxiety or depression.

ENDOCRINE: No excessive urination or excessive thirst.

DERMATOLOGIC: No rashes or skin changes.

MEDICAL HISTORY:

PAST MEDICAL HISTORY: Hypertension

PAST SURGICAL HISTORY: Cholecystectomy 1990s, right knee surgery 1994, tonsils/adenoids, tubal ligation.

FAMILY HISTORY: Parents are both deceased, mother had CVA at age 74 and father MI at age 72.

MEDICATIONS: Ibuprofen, 200-800 mg as needed.

ALLERGIES: No known drug allergies.

OCCUPATIONAL HISTORY:

Has worked as a nurse last 20 years, with the last 4 years at XYZ County Hospital District.

SOCIAL HISTORY:

High school graduate. Married 25 years with 3 adult children. Drinks approximately 0-1 alcoholic beverages per day. Non-smoker. No history of substance abuse. Sleep is undisturbed. No history of psychological distress or treatment.

PHYSICAL EXAMINATION:

VITALS: 65 inches, 148#, BP 122/84, Pulse 76, Respiration 16

The IE has a somewhat flat affect but was cooperative with history and examination. She was oriented to time, person and place, with normal attention span and concentration.

The IE was able to rise from sitting to standing without signs of dysmetria. She ambulates with normal gait. There is no evidence of spasticity, ataxia or other gait deviations due to weakness.

Her lumbar spine has no visible deformity, such as lumbar list, scoliosis, or kyphosis. There is a 2 cm midline scar at L4/5 level. While she is tender on the right side of the spine and has mild withdrawal with palpation, this is not to be confused with "spasm".

Functionally, she can walk on heels and toes, squat and perform 10 calf raises on each leg without signs of weakness distally or proximally. This is consistent with manual muscle testing which shows 5/5 strength bilaterally of the gluteus maximus, hamstrings, gluteus medius, quadriceps, tibialis anterior, extensor hallucis longus, and peroneal muscles. There was some palpatory tenderness but no spasm of the right lumbar paraspinal muscles and right gluteal muscles. The patellar and Achilles DTRs are 2+ bilaterally. Medial hamstring reflexes are not obtainable bilaterally.

There is no visible general or focal atrophy of lumbar paraspinals or lower extremity muscle groups. Bilateral lower extremity sensation is normal. Normal pedal pulses. Calf circumference: right = 28 cm; left = 27 cm. Thigh circumference (10 cm proximal to superior pole of the patella): right = 58 cm, left 57 cm.

She has minimal sensory alterations in a distal right L5 distribution (dorsum of the foot) without other dermatomal sensory loss or alteration.

Lumbar range of motion is decreased with the claimant bringing her fingertips to within 9 inches of the floor on forward flexion, estimated at 60 degrees of flexion. This produced end-range right low back and right buttock pain. No radicular pain was reproduced. Lumbar extension and right and left lateral extension are mildly restricted but not painful. There is uniform movement right and left.

Supine straight leg raise is accomplished to 70 degrees on the right where it reproduces low back pain, with complaints of increased back pain with ankle dorsiflexion. Supine straight leg raise is 75 degrees on the left, limited by hamstring tightness. Prone hip extension with knee flexion is limited only by hip flexor tightness. Sitting SLR is 80 degrees with hamstring tightness/discomfort only. Other clinical exam tests of the hip and SI joint / pelvis (FABER, FADIR, SI Distraction, etc) were negative for reproduction of back or buttock pain. There were 0/5 Waddell signs.

ISSUES TO BE ADDRESSED:

Extent of Injury – Question: Was the accident or incident giving rise to the compensable injury a substantial factor in bring about the additional claimed injuries or conditions, and without it, the additional injuries or conditions would not have occurred? In this case, the additional claimed injuries are lumbar degenerative disc disease, L4/5 disc herniation and L5 radiculopathy.

Lumbar spondylosis is a degenerative condition whereby the spine undergoes slow insidious loss of its original structure. This can also be known as lumbar “**degenerative disc disease**”. This process can include the intervertebral discs (referred to after this as discs) and adjacent vertebral bodies and the facet joint. Signs of spondylosis may be disc desiccation and loss of height, disc bulges, and **disc herniations** (protrusions and extrusions). There can also be vertebral end-plate sclerosis and bony spurring, ligamentum flavum thickening and facet joint hypertrophy. All the above can result in stenosis at one of 3 potential anatomic locations in the spinal canal.

Radiculopathy means bad nerve root. Radiculopathy can be due to disease (diabetes, toxin, etc.), slow insidious compression (stenosis) or trauma (fractures, dislocation and traumatic herniations). An injury related radiculopathy should demonstrate some compression or deflection within the spinal canal and should correspond to clinical findings to that nerve root. Clinical signs of radiculopathy are a dermatomal distribution of abnormal sensation, possible myotomal distribution of weakness, corresponding reflex

changes and atrophy. Electrodiagnosis may confirm motor axonal injury but is not always positive even in those with clinical radiculopathy.

The mechanism of injury as reported to me today was “*she restrained a violent patient*”. This was inconsistent with the medical records previously discussed. The records reflect a trip and fall. Ms. Doe presented on 08/25/22 with complaints of low back pain and proximal **left** lower extremity pain. She was diagnosed with a lumbar sprain/strain on 8/25/22. X-rays confirmed pre-existing degenerative disc disease with facet hypertrophy. This was confirmed by the first lumbar MRI that demonstrated these findings but no acute findings (and no evidence of a disc herniation). The degenerative disc disease and facet hypertrophy in all reasonable medical probability pre-existed the 8/25/22 accident and are “*ordinary diseases of life*”. The evidenced based medicine by several authors (see reference list) discusses the findings of spondylosis increasing with each decade of life in the asymptomatic population. While pre-existing conditions may be aggravated, there must be “*additional injury or harm*”. There are no findings from imaging that demonstrate the facet hypertrophy and degenerative disc disease were either caused by or aggravated by the events of the date of injury

Then nearly 2 months later when there had previously been no objective signs of radiculopathy on either side, sneezing 3 days prior to her 10/30/22 visit with Dr. Zhivago resulted in a switch of her pain from the left to the right side. It is my opinion that this non-injury event caused the disputed conditions of the right sided L4/5 disc herniation and right L5 radiculopathy, and this was confirmed by the difference in the MRI scan images and reports from the initial 09/01/2022 and 11/07/2022 after the non-injury event. This was discussed above.

Whereas the neurologic exam on the right had previously been normal, the claimant manifested radicular leg pain after the non-injury event. While there was evidence of an eventual right sided radiculopathy that matched the MRI findings, these were a late presentation without temporal relationship to the DOI, and opposite the initial side of leg symptoms.

In summary, based on my review of the medical records, the medical history and my examination, and application of a causation analysis, it is my medical opinion within reasonable medical probability that the mechanism of injury on 8/25/2022 **were not** a substantial factor in causing or aggravating a L4/5 disc herniation, L5 radiculopathy, degenerative disc disease or fact hypertrophy. The 8/25/22 compensable injury is limited to a lumbar sprain/strain.

Maximum Medical Improvement – Question: Has MMI been reached; if so, on what date?

Certification #1:

The medical records, medical history and exam show that Ms. Doe sustained a lumbar sprain/strain that was superimposed on degenerative disc disease and facet hypertrophy of the lumbar spine. She sustained the large right L4/5 disc herniation and right L5 radiculopathy when sneezing 3 days prior to her visit with Dr. Zhivago on 10/30/22, as documented in the records.

Ms. Doe reached MMI for compensable injury of a lumbar sprain/strain after completing appropriate ODG recommended treatment for a lumbar sprain/strain. This occurred on 10/10/22 when she completed the appropriate physical therapy for the lumbar sprain/strain. Her exam on the last day of therapy was benign with some residual complaints of mainly left sided LBP, but near full ROM and a normal neurologic examination. There was no anticipation of further material recovery after that date.

While she may have met indications for surgery during her treatment course, AFTER the 2nd MRI, this was not due to the injury event and therefore will not be considered in the discussion of MMI For this certification. My opinion corresponds to this certification.

Certification #2

If it is determined that the additional claimed injuries for the late appearing right sided low back and radicular symptoms are compensable, the claimant did not reach MMI until AFTER ODG recommended treatment for the right sided radiculopathy. Ms. Doe saw James Kildare, MD who documented a “positive SLR” for right buttock pain. He did not record any clear neurologic deficits. He performed an L4/5 microdiscectomy and laminotomy on 12/27/22. She completed 14 visits of post-operative physical therapy. The last therapy note documented some persistent right sided LBP and a distal L5 sensory loss, but no loss of L5 reflex and it was stated that there was no atrophy and no residual dural tension signs. She was released to by Dr. Kildare to return as needed on 04/03/23. There was no anticipation of any further material recovery after that date.

Impairment Rating – Question: As of the MMI date, what is the IR?

Certification #1:

On the date of MMI, **10/10/2022**, the records show that Ms. Doe had low back pain, but no significant clinical findings, which corresponds to lumbosacral DRE Category I, which is 0% whole person. I find no objective evidence of impairment upon my physical exam or review of her medical records proximate to the date of MMI which corresponds with a higher DRE category.

Certification #2

Proximate to the chosen date of MMI of 04/03/23, the records show that Ms. Doe had right sided low back pain, but with minimal residual radicular findings. This is consistent with my examination, therefore, since my exam is more complete, will be used to reflect the IE’s condition for the IR on the date of MMI.

This was the only differentiator that would put her in a lumbosacral DRE Category II, which is 5% whole person. I find no objective evidence of impairment upon physical exam or review of her medical records (including Dr. Kimble’s exam) which corresponds with a higher DRE category such as DRE III. While there is minimal residual and stable radicular signs, she does not meet the threshold differentiators for a DRE III, such as decreased or lost reflexes or atrophy equal to or greater than 2 cm (“significant signs”) as per the 4th edition of the AMA Guides and relevant Appeals Panel Decisions.

CONCLUSION: In summary, it is my opinion based on the available medical records, my certifying examination, review of the imaging in this claim and the EBM, that Jane Doe's 8/25/22 compensable injury for purposes of MMI/IR is a lumbar sprain/strain. She reached MMI on 10/10/22 and has a 0% whole person impairment from lumbosacral category DRE I.

Thank you for the opportunity to assist in this case. Please let me know if you have any questions.

Darrell B. Wisdom, M.D.

Board Certified Orthopedic Surgery

Texas License H9999

cc:

Jane Doe

TDI – DWC

Yuri Zhivago, M.D. (Treating Doctor)

Acme Insurance C/O

Ben Matlock

Mailed Certified 07/23/23

Sent by Fax 1-(800) 555-1212 on 07/19/23

Sent by Fax 1-(800) 555-1212 on 07/19/23

Sent by Fax 1-(800) 555-1212 on 07/19/23

(Carrier Law Firm) 123 Anytown, Texas 77777

REFERENCES:

American Journal of Neuroradiology. **Nomenclature of Lumbar Disc Pathology.** The Joint Task Force) asnr.org/spine_nomenclature/discussion.shtml

AMA Guidelines to the Evaluation of Permanent Impairment. (4th Edition). Published by the American Medical Association, 1993 and 2001.

Boden SD, Davis DO et al. **Abnormal Magnetic Resonance Scan of the Lumbar Spine in Asymptomatic Subjects.** The Journal of Bone and Joint Surgery. Vol 72-A, No3, March 1009.

Brinjikj W, Luetmer PH, Comstock C, Bresnahan BW et al. **Systematic Literature Review of Imaging Features of Spinal Degeneration in Asymptomatic Populations.** American Journal of Neuroradiology. <http://www.ajnr.org/content/early/2014/11/27/ajnr.A4173>.

Dumitru D, Amato AA, Zwarts MJ. **Electrodiagnostic Medicine, Second Edition.** Hanley & Belfus, Philadelphia PA. 2002. [Radiculopathies p 713-716.]

Jensen MC, Brant-Zawadzki MN et al. **Magnetic Resonance Imaging of the Lumbar Spine in People without Back Pain.** NEJM. July 14, 1994, Vol 331, No 2.

Matsumoto M, Fujimura Y, Suzuki et al. **MRI of Intervertebral Discs in Asymptomatic subjects.** The Journal of Bone and Joint Surgery. Vol 80-B, No1, January 1998.

Official Disability Guidelines. [Online Edition](#). Work Loss Data Institute, 169 Saxony Road, Suite 101, Encinitas, CA 9202

Weishaupt D, Zanetti M. et al. **MR Imaging of the Lumbar Spine: Prevalence of Intervertebral Disk Extrusion and Sequestration, Nerve Root Compression, End Plate Abnormalities, and Osteoarthritis of the Facet Joints in Asymptomatic Volunteers.** Radiology 1998; 209: 661-666.



Edwin Pain M.D.

License H4422 TX

DD Assignment #432

DESIGNATED DOCTOR EXAMINATION

Employee: Vega Laredo

Date of Birth: 1.15.1971

Date of Injury: 03/08/23

Last 4 SSN: 4312

DWC No: 20888539

Carrier Accepted Diagnoses: Right shoulder Strain

Insurance Carrier: Pretty Good Insurance

Carrier Claim No: XX300000258

Employer: EZ Construction

Treating Doctor: Stanley Feelgood, MD

Exam Location: 4444 Trailhead Hollow, Austin, TX 78746

Exam Date: June 26th, 2023

Time of Examination: 9:30 to 10:45 am

*NOTE: This does not include the time to review and dictate the records prior to the evaluation, dictate examination findings, medical research and analysis and synthesis of the records with the history and physical and the time to develop appropriate opinions.

I have no known disqualifying association as described in [28 Texas Administrative Code Section 127.140 \(relating to Disqualifying Associations\)](#)

PURPOSE OF THE EXAMINATION:

I have been requested to evaluate the identified injured employee (IE) for a DESIGNATED DOCTOR EXAMINATION for the following purposes as per the DWC 32: **Maximum Medical Improvement and Impairment Rating**

I am a certified Designated Doctor in good standing with the Texas Department of Insurance – Division of Worker's Compensation (TDI – DWC). I have no disqualifying associations (one that may reasonably be perceived as having potential to influence my conduct or decision) and do not participate in any worker's compensation networks.

I counseled the claimant as to my role as Designated Doctor and that no doctor – patient relationship would exist because of this evaluation. We discussed the concept of Maximum Medical Improvement and Impairment Rating, the guidelines that are utilized for their determination and the necessity that all opinions must be based on reasonable medical probability and evidenced based medicine.

The examination was conducted with review of the documentation indicated below and a face to face medical history and examination. I discussed the importance of giving full effort, without causing harm. It was my opinion that the examination findings were consistent with the clinical record.

RECORDS REVIEWED:

Darn Good Urgent Care (DGUC) Austin, Texas / Stanley Feelgood, MD – 03/09/23, 03/15/23, 03/29/23, 04/22/23, 04/26/23, 05/03/23, 05/31/23

Darn Good Urgent Care (DGUC) Austin, Texas / PT Evaluation and subsequent treatments- 03/10/23, 03/12/23, 03/14/23, 03/19/23, 03/21/23, 03/26/23, 03/28/23, 04/02/23, 05/14/23, 05/16/23, 05/21/23, 05/23/23, 05/28/23 and 05/30/23.

DWC-73 - 03/15/23

DWC Form 1 – 03/15/23

**Premier Medical Imaging - MRI of the Right Shoulder – 04/19/23,
OK Orthopedics, Austin, Texas / Frank Bonebreak DO – 05/02/23, 05/08/23,
UR Company – 03/10/23, 06/05/23,
Peer Review Company / Pierre Badass MD – 05/23/23**

PLN-11 – 05/28/23

DWC 32 – 06/05/23

OA-32A – 06/08/23

Carrier Timeline

Images (CD) of MRI of the Right Shoulder - Premier Medical Imaging – 04/19/23 - Provided by Carrier

MECHANISM OF INJURY:

The IE is a 52-year-old right hand dominant male with a reported DOI of 03/09/23. He reported loading a heavy lumber carrier on two sets of wheels, full of stacked lumber. The carrier started to tip over and the lumber shifted to the right. He tried to catch the wood load with his right arm and hold the carrier with his left arm to stop it from tipping over completely. He felt a sudden and heavy pulling to his right arm from a partial abducted position. The IE described immediate pain and an audible / palpable pop at his superior lateral right shoulder. Within hours he had difficulty lifting his right arm in front or to the side.

COMPLAINTS:

After a few days to weeks of resting the shoulder, his pain diminished, and he was able to move the right arm better, passively than actively. As he returned to normal duties, he experienced more pain and decreased range of motion. Active movement at and above the shoulder level hurts worse. His shoulder intermittently clicks or pops in the location of the original pain. The pain can radiate to the right side of the neck. He denies worsening shoulder pain with head or neck movements or with coughing or sneezing. The shoulder can ache to the upper arm, but he denies pain or paresthesias into his right forearm and hand. When certain movements cause sharp pain, his shoulder feels weak. He denies weakness in the biceps or his grip.

MEDICAL CHRONOLOGY: (Time spent reviewing Medical records/history: 1 hour and 45 minutes)

03/08/23 Date of injury – Darn Good Urgent Care (DGUC) Austin, Texas / Stanley Feelgood, MD: The IE reported he was loading a heavy wood wheelbarrow when it tipped. He tried to catch the wood load with his right arm which resulted in his shoulder injury. He felt a sharp pull and a pop at the outer front shoulder. He rated his pain as 5-8/10 in his right shoulder. He denied numbness / tingling, weakness, swelling and bruising. His past medical history included a right knee surgery, a prior AC joint injury on the right and a Grade V AC joint separation on the left. He denied any chronic / prior medications.

On examination there was no tenderness at the AC joint but point tenderness at the anterior greater tuberosity. ROM was decreased in flexion, abduction and external / internal rotation. Reflexes were normal. Strength in the deltoid, supraspinatus (SS) > infraspinatus (IS) was decreased due to pain. Provocative maneuvers were not performed due to acute pain.

Right shoulder x-rays on that date revealed no fracture or dislocation.

The diagnosis rendered by Dr. Feelgood was “*right shoulder strain*”. The plan was for PT, and he was prescribed Naprosyn and Tramadol. An arm sling was given, he was to use ice as needed and return for recheck in 1 week.

The DWC 73 returned the IE to work with restrictions including no lift/carry more than 1 pound through 06/16/15.

03/10/23 – DGUC - PT Evaluation: The IE reported he was “*lifting cut wood when it moved and hurt his right shoulder*”. He reported the pain could radiate to his elbow. He experienced muscle tightness around the shoulder and sharp pain when trying to reach behind his back or overhead. He rated his current right shoulder pain as 4/10 and 6/10 without medications.

On examination, right shoulder ROM in degrees was: flexion 45, extension 30, abduction 52, adduction 4 and internal rotation to the right greater trochanter and external rotation to the right ear. Strength was 4 / 5 in the deltoid, supraspinatus (SS) > infraspinatus (IS). The plan was for PT 3 times per week for 2 weeks.

03/10/23 – Coventry – Pre-Auth and Case Summary Report: A request for PT 3 times a week for 2 weeks for right shoulder was deemed medically necessary.

03/10/23 – DGUC - PT: Additional dates of service were 03/12/23, 03/14/23, 03/19/23, 03/21/23, 03/26/29 and 03/28/23 (6 visits plus eval).

03/15/23 - DWC Form 1: The date of injury was listed as 03/08/23 and was reported on the same day. The IE alleged a right shoulder strain due to “*lost balance picking up lumbar, trying to keep lumbar from falling*”. His occupation was a carpenter. His date of hire was 04/26/15.

3/15/23 – DGUC / S Feelgood MD: This was 1 week after the DOI. He noted improvement with PT and oral steroids and shoulder pain of 1-2/10. On examination the doctor stated that ROM was much improved, but there was a “*persistent impingement interval*” pain. Tenderness was decreased, and muscle testing and reflexes were normal. Crepitus was noted with shoulder movement. The diagnoses did not change. The plan was to continue PT and take over the counter medications as needed. “*Advance duties per findings today*”. Return for recheck in 2 weeks.

03/15/23 – DGUC / S Feelgood MD - DWC-73 This continued the IE to work through 03/31/23 with restrictions including discontinuance of the arm sling and keeping repetitious or forceful push / pull to a minimum. He was to limit overhead reaching and was restricted to no lift / carry more than 10 pounds. He was advised to take OTC medications.

3/29/23 – DGUC / S Feelgood MD: On that date the IE reported much improvement with PT and oral steroids. Shoulder pain on that date was 1-2/10, but he was still only doing supervisory work.

On examination, Dr. Feelgood noted “**full ROM of his right shoulder**”, but with pain through the impingement interval. He had a “**partially positive Drop Arm Test, a positive Hawkins-Kennedy test and a mildly positive Yergason’s test**”. There was no biceps defect. He had a “**negative lift off test**” for subscapularis pain and had a “**negative apprehension**” test in supine. Tenderness was decreased but persistent at the greater tuberosity. SS strength testing was decreased due to pain. Mild glenohumeral crepitus was noted with movement. There was no AC joint pain.

The diagnoses did not change. The plan was to continue PT and take OTC meds as needed. Advance duties per findings today. Return for recheck in 2 weeks. The DWC 73 on that date continued the IE to work with restrictions of no above shoulder movement and no lift / carry of more than 15 pounds.

04/02/23 – DGUC – PT Re-Evaluation: The IE reported that he was doing home exercises and only supervising at work. His shoulder pain was rated as 4/10

On examination, right shoulder ROM in degrees was flexion 148, extension 35, abduction 140, adduction 15 and internal rotation to L5 and external rotation to T4. IR was more guarded and painful than ER. Strength was -4- to -5 / 5. The PT noted the IE was progressing towards goals but continued with some deficits. It was reported he had initial improvement after rest in a sling and restricted duty work. Additional PT was recommended.

04/12/23 – DGUC / S Feelgood MD: The IE reported he was doing better in PT, but still had daily pain that was worsened when lifting with the right shoulder. The treating doctor requested an MRI.

04/19/23 - Premier Medical Imaging - MRI of the Right Shoulder: The IE was referred by Dr. Feelgood. The indications for this examination were **“Right Shoulder Pain, suspect supraspinous tear”**. The exam was 6 weeks out from the DOI. The radiologic impression by Dr. Painful was:

1. **0.8 x 2.6 cm high grade partial thickness tear of supraspinatus tendon without retraction**
2. **Mild tendinosis of the supraspinatus**
3. **No evidence for other rotator cuff tear or tendinosis**
4. **No significant atrophy (fatty infiltration) of rotator cuff musculature**
5. **Mild AC joint arthrosis**
6. **Minimal subacromial spur**
7. **No thickening of the coracoacromial ligament**
8. **No AC joint sprain or GH capsular sprain**

[I also reviewed the images from this MRI I agree with the findings of the radiologist. There was no significant fatty atrophy of the supraspinatus muscle.]

04/26/23 – DGUC / S Feelgood MD: On that date, 7 weeks after the DOI, the IE rated his right shoulder pain was 6/10. His pain was increased by returning to work activities. He tried to restrict use of the right arm but use of the nail gun increased the local pain in his shoulder, making his arm ache and go heavy. He stated his shoulder **“was still popping with everything he did, and it hurt to lift his arm overhead”**. Results of the MRI of the right shoulder were reviewed. The doctor explained there was a partial thickness rotator cuff tear and some other minor changes.

On examination tenderness and ROM were unchanged. The diagnosis remained as right shoulder strain, but the treating doctor added, partial thickness tear of supraspinatus tendon without retraction, tendinosis of the supraspinatus and Mild AC joint arthrosis. He recommended additional PT for the shoulder and made a referral for a surgical opinion.

05/02/23 - OK Orthopedics / Frank Bonebreak, DO: The IE was seen for evaluation of the right shoulder. The IE reported an acute onset of right shoulder pain while lifting about 60 pounds of 2x4's by himself while at work 3 months prior. He noted an AC joint sprain as a youth, but no history of limitations for the past 40 years. He reported constant right shoulder pain significantly aggravated by any shoulder activity, especially overhead. The pain was predominantly anterolateral, with intermittent cracking and popping of shoulder with certain ROMs. The IE had pain when elevating the arm greater than 70-80 degrees, with diminished pain once past shoulder height. His past treatment included medications and 10 or so sessions of PT. The IE rated his pain as 9/10.

Right shoulder x-rays on that date showed **“8.7 mm acromiohumeral interval with type II acromion”**. There was no proximal migration of the humeral head. Mild AC degenerative changes were noted.

On examination, there was no evidence of deformity or atrophy of the right shoulder girdle. “Popeye’s sign” was negative. Tenderness was at Codman’s area. Passive ROM of the right shoulder was full. Active ROM was described as “limited” in abduction and forward flexion. Cross Arm Test was negative. Speed’s test and Yergason’s test for the biceps was mildly positive. O’Brien’s negative. Impingement tests was markedly positive. Distal radial, ulnar, median nerve and motor function were “intact”.

The impression given on that date was **“tear right rotator cuff”**. Dr. Bonebreak recommended a trial of subacromial steroid injection and continued PT.

05/03/23 – DGUC / S Feelgood MD: There was no significant change in the history, exam or diagnoses. The IE informed the doctor that an injection was pending. The doctor did not have Dr. Bonebreak's report. He requested pre-authorization for further therapy.

05/05/23 – UR Company: This was an approval for a request for PT 3 times a week for 2 weeks (6 sessions).

05/08/23 - OK Orthopedics / Frank Bonebreak, DO: An injection was performed into the *subacromial space* under fluoroscopic guidance. The patient tolerated the injection well. There was *"immediate reduction of pain with AROM during the anesthetic phase of the injection"*.

Dr. Bonebreak's assessment was that the *"rotator cuff tear"* condition remained symptomatic. He stated, *"I conclude the aforementioned diagnoses were causally and proximally related to the work-related injury. The mechanism of injury and description of the incident are consistent. It is more likely than not that the diagnoses are a result of the work-related injury."* He reviewed the treatment options including PT, orthotics, steroid injections and surgery.

05/14/23 – DGUC PT: On that date the IE reported pain was as 2/10 at rest but up to 7/10 after use of the arm, especially overhead. The IE stated he was considering surgery but understood that he needed to try more therapy. Additional dates of service included 05/16/23, 05/21/23, 05/23/23, 05/28/23 and 05/30/23.

On 05/30/23, the IE rated his pain as 6/10 pre-treatment and 7/10 post treatment. He also reported difficulty sleeping. His exam continued to demonstrate slight improvement in active ROM, but persistent pain in the impingement interval. His strength of the rotator cuff muscles was improving by ½ a muscle grade. Due to improvements, additional therapy was recommended.

05/15/23 - DWC 41: The date of injury reported was 03/08/23. This indicated the IE was *"moving a heavy piece of wood that was on a moving cart when the cart came forward. Tried to catch 80 lb. piece of wood and injured right shoulder"* His occupation was listed as a carpenter.

05/23/23 – Pierre Badass MD – Peer Review: Dr. Badass reviewed the medical records and summarized them accurately. He opined that the rotator cuff tear and all other MRI findings were degenerative, and that the compensable diagnosis was a right shoulder strain. No further treatment after the initial round of PT was necessary or related to the compensable injury.

05/28/23 – PLN-11: The carrier determined compensable injury as a shoulder strain. They denied that the high grade partial thickness tear of supraspinatus tendon without retraction; Mild Tendinosis of the supraspinatus, and Mild AC joint arthrosis were compensable.

05/31/23 – DGUC / S Feelgood MD: There was no significant change in the history, exam or diagnoses. A total of 12 PT sessions were completed. The PT had recommended additional PT based on the improvements demonstrated. Dr. Feelgood requested pre-auth for further therapy.

06/05/23 – UR Company: Additional therapy was denied based on the PLN-11

06/05/23 - DWC 32 - Request for Designated Doctor Examination: This was completed by carrier representative. The purpose of the examination was MMI / IR.

06/08/23 - OA-32A - Commissioner Approval of Designated Doctor Examination

FAMILY / SOCIAL / OCCUPATIONAL HISTORY:

Mr. Laredo is employed as a carpenter and has been with this employer for 2 years. He is a working supervisor; therefore, he still must be capable of all job duties as his employees. Mr. Laredo has a HS education plus a couple years of college. He is married with 2 grown children. He does not smoke (smoked for 5 years and quit in 1985) and does not drink alcohol except socially.

GENERAL HEALTH HISTORY:

Medical Illnesses / Conditions: The IE has no chronic medical conditions.

Surgical History: 1. 2004 – Left Peroneal tendon surgery, 2. 2017 - Umbilical hernia repair

Prior Injuries: 1. 4th degree shoulder separation left shoulder after fall off a bike, 2. Prior left ankle tendinitis.

Family History: Lung cancer in father.

Primary Care Physician: None provided.

Drug Allergies: None.

Current Medications: He is not any chronic medications for health reasons. He takes OTC NSAIDs for his shoulder.

PHYSICAL EXAMINATION:

The IE appeared his stated height of 6' 0", weight of 195 pounds and well-muscled. The Injured Employee, Vega Laredo was identified by his driver's license. His movement patterns in the lobby and in the exam room were consistent with demonstrated movement patterns when formally measured later. He ambulated without any significant gait deviations secondary to spasticity / myelopathy.

There was no significant deformity of Mr. Laredo's cervical, thoracic or lumbar spine. His cervicothoracic spine demonstrates no evidence of torticollis, increased paracervical or parathoracic rigidity / spasm. The thoracolumbar spine demonstrated no postural or fixed kyphosis nor scoliosis. There was no acute spasm or guarding of the muscles of any of the spinal regions. A brief screen of the cervical spine demonstrated no tenderness at the occiput, the cervical spinous processes or the facet joint regions. There was minor tenderness in the right upper trapezius / levator scapula junction. Cervical ROMS did not reproduce shoulder pain.

There was no evidence of scapular winging with the arms neutral at the side or with movement into forward flexion. With hands on hips posture, the IE expressed presence of discomfort that the right anterior superior shoulder at the greater tuberosity. There was increased muscular tightness and fixation of the scapula with passive mobilization of the scapula and the GH joint on the right, but not on the left.

The left shoulder demonstrated findings consistent with the prior 4th degree left AC joint injury. The left AC joint was hypertrophic. Other than accentuating the deformity on the left, provocative shoulder maneuvers performed on the left were not painful. Active left shoulder ROM was full in all planes except a painless 20-degree loss of abduction on the left.

On examination of the right upper extremity, there was no evidence of deformity or atrophy involving the right shoulder girdle, including the AC joint. "Popeye's sign" was negative. There was no atrophy in the suprascapular / infrascapular fossa by inspection or upper arms/forearms by measurement. Tenderness was present at the anterolateral greater tuberosity at the supraspinatus insertion. There was mild hypertrophy or the right AC joint, but there was no tenderness to palpation.

Inspection of the remaining joints of the upper and lower extremities revealed no soft tissue swelling, erythema or warmth and no synovitis of the joints or tenosynovitis of the tendons of the hand and wrist or foot and ankle. The only exceptions were minor age -related degenerative changes of the joints of the digits bilaterally. There are no unusual rashes, nodules or skin manifestations of the connective tissue disorder. His nails had a normal appearance as well. There were no associated temperature changes, swelling or deformities of the distal upper extremities. There were minor symmetric degenerative changes of bilateral hands.

The sensory exam was normal and there were symmetric biceps and brachioradialis reflexes. The right triceps reflex was diminished due to guarding at the shoulder. Manual muscle testing was 5/5 in all muscle groups except 4/5 at the supraspinatus and infraspinatus due to pain at the greater tuberosity.

The right shoulder had a partially positive Drop Arm Test, a positive Hawkins-Kennedy test and a mildly positive Yergason's test. Crossed Adduction / Scarf test was negative for AC joint. Pain. There was a negative lift off test for subscapularis pain and negative anterior apprehension test in supine.

Passive ROM of the right shoulder was full. Active right shoulder ROM in degrees was flexion 150 and abduction 145 (both with a positive impingement interval from 85 to 110 degrees,) Extension 35 and Adduction 15. Internal rotation from 90 degrees abduction was to 15 degrees and painful at the prior identified area of focal tenderness. External rotation from 90 degrees of abduction was to 60 degrees. There was negative glenohumeral translation, but positive crepitus during active movement patterns.

DIAGNOSES:

Right Shoulder Strain
Right High-Grade Partial Rotator Cuff Tear

DISCUSSION:

I was asked to determine MMI and IR. TLC&408.001(a)(1), 408.123(a) and 28&TAC130.1(b)(4) & (c)(3) support that that the DD defines the compensable diagnoses. Once the diagnoses have been defined, the ODG (the adopted guideline for MMI) can be applied. Without a complete EOI analysis, I will walk through my opinion regarding the compensable diagnoses. The initial mechanism as described to me was significant in the magnitude of the weight that the IE was trying to restrain from falling. The mechanism of a forceful distraction injury to the right shoulder in abduction, would result in a forceful eccentric contraction of the right supraspinatus muscle and would be consistent with a mechanism to cause an acute supraspinatus tear. While there was evidence of likely age-related tendinosis in the supraspinatus muscle, the events of the date of injury were a substantial factor in producing an aggravation and more likely than not a superimposed acute tear.

An acute tear of the supraspinatus is supported by the initial complaints and consistent location of complaints to the rotator cuff insertion. The IE demonstrated the initial severe burning was exactly along the line of fiber direction in the supraspinatus tendon and muscle. The IE pointed along the length of the muscle rather than more medial at the medial scapular border and not over the AC joint. An acute rotator cuff tear is supported by the initial clinical findings and the consistent clinical findings that persisted after resolution of the acute injury pain. The location of complaints and the clinical findings are consistent with the location of the rotator cuff tear. I am aware of the EBM literature that demonstrates an increasing proportion of the asymptomatic population have imaging evidence of partial to complete rotator cuff tears with increasing age. However, with consistency of the mechanism, the subjective complaints and the objective findings, it is my opinion that the rotator cuff tear is medically probable to be a result of the events of the DOI.

The mechanism of injury is not consistent with the type that causes an AC joint injury. The subjective complaints and the clinical findings have not been consistent with a symptomatic AC joint. I therefore did not include any AC joint diagnoses as compensable.

MAXIMUM MEDICAL IMPROVEMENT(MMI):

Statutory Maximum Medical Improvement is defined as 104 weeks from the date on which income benefits begin to accrue. **Clinical Maximal Medical Improvement** is defined as *"the earliest date, after which based on reasonable medical probability further material recovery from or lasting improvement to any injury can no longer be anticipated."*

With inclusion of the diagnosis of the high-grade partial thickness rotator cuff tear, and considering the ODG, including Appendix D, there are additional treatments that would be anticipated to result in further material recovery. This can include additional conservative care and potential surgery. For that reason, it is my opinion that the IE is not at MMI.

IMPAIRMENT RATING:

Chapter 3 would be utilized to determine the impairment for the upper extremity. However, since I determined that the IE was not at MMI, an IR cannot be determined. Rule 130.1 states that the IE's IR must be determined by their condition at MMI.

The DWC-69 will reflect the compensable diagnoses determined by this Designated Doctor's certifying examination. It will reflect that the IE is NOT at MMI.

All opinions rendered are based on reasonable medical probability. My opinions are based on the records provided as per the documentation listed. If more information becomes available at a later date, an additional service / report / reconsideration may be requested. Such information may or may not change the opinions rendered in this evaluation. This determination is rendered in accordance with "Evidence-based Medicine" (EBM). EBM is the use of current best quality scientific and medical evidence formulated from credible scientific studies, including peer-reviewed medical literature and other current scientifically based texts, and treatment and practice guidelines in making decisions about the care of individual patients. In lieu of these, I relied upon generally accepted standards of medical practice recognized in the medical community that are relied upon in addressing the issues of this Medical Record Review.

Edwin Pain, MD

Texas Department of Insurance – Division of Worker's (TDI-DWC) – Designated Doctor

Dictated, reviewed, opinion verified, and attested to by my original and electronic signature.

I filed this report by verifiable means with the injured employee, injured employee's representative, treating doctor and insurance carrier.

Enclosures: DWC-69

cc. Pretty Good Insurance (Faxed to 888-442-4422 on 06/30/129)
 Carrier Attorney (Faxed: 512-555-1212 on 06/30/23)
 Claimant's Attorney (Faxed: 210-555-1234 on 06/30/23)
 Vega Laredo (Mailed: 826 Hurting Road, Austin, TX 78757)

REFERENCES:

Gill TK, et al. Prevalence of abnormalities on shoulder MRI in symptomatic and asymptomatic older adults. *Inter J Rheumatic Diseases*. 2014;17:863-871.

Miniaci A, et al. Magnetic resonance imaging evaluation of the rotator cuff tendons in the asymptomatic shoulder. *Am J Spots Med*. 1995;23(2):142-145.

Milgrom C, et al. Rotator cuff changes in asymptomatic adults: the effect of age, hand dominance, and gender. *J Bone Joint Surg Br*. 1995;77:296-298.

Sher JS, et al. Abnormal findings on magnetic resonance images of asymptomatic shoulders. *J Bone Joint Surg Am*. 1995;77:10-15.

Tempelhof S, et al. Age-related prevalence of rotator cuff tears in asymptomatic shoulders. *J Shoulder Elbow Surg*. 1999;8:296-299.